
Case Report: Gastric Trichobezoar with Small Bowel Obstruction

Caglayan K MD^a, Koc A MD^b, Isler B MD^c, Dogan H MD^d, Kutluk AC MD^e

Departments of General Surgery^a, Radiology^b, Anesthesia^c and Reanimation, Emergency Medicine^d, Thoracic Surgery^e, Kars State Hospital, Kars, Turkey

Abstract

Trichobezoars are hair impactions usually located in the stomach. Occasionally, they have a tail that extends to the cardia, pylorus, and duodenum, or even further to the jejunum and ileum. In some cases, the impaction becomes dislodged and causes small bowel obstruction. In children, bezoars are associated with pica, mental retardation, and coexistent psychiatric disorders. We describe a 4-year-old girl in whom a gastric trichobezoar resulted in failure to gain weight, iron deficiency anemia, a painless epigastric mass, and ileus. Surgical excision was followed by complete uncomplicated recovery.

MeSH Words: trichobezoar, gastric; management; bowel obstruction

Introduction

Trichobezoars are gastrointestinal masses formed from the accumulation of ingested hair. Occasionally, they have a tail that extends to the cardia, pylorus, and duodenum, or even further to the jejunum and ileum. When the entire small intestine is involved, the disorder is called Rapunzel syndrome. In some cases, the impaction becomes dislodged and causes small bowel obstruction.

Trichobezoars are most common in children and adolescents with normal gastrointestinal function but with behavioral disorders associated with the ingestion of foreign substances [1]. The clinical findings depend on the location of the bezoar. Gastric bezoars may manifest as dyspepsia,

nausea and vomiting (64%), colicky abdominal pain (70%), alteration of bowel habits (32%), and anorexia, weakness, weight loss and cachexia [2]. Complications include bleeding, obstruction, and gut perforation. Distal extension of the bezoar can lead to protein-losing enteropathy and steatorrhea. Acute pancreatic necrosis, obstructive jaundice, hypochromic anemia, vitamin B12 deficiency, and abdominal mass have also been reported [3]. Although alopecia is a common accompanying sign, some patients may not have evidence of hair loss [4]. Halitosis may be present due to the decomposition and fermentation of fats trapped in the interstices of the bezoar [5]. The final diagnosis is based on a careful history, thorough physical examination, and radiologic evidence.

Emergent surgical intervention may be required [3].

The aim of the present study was to describe a 4-year-old girl with small bowel obstruction due to a gastric trichobezoar.

Case Report

A 4 year-old girl presented to the emergency department with complaints of abdominal pain and distension, in addition to anorexia of 2 years' duration. Her mother reported poor weight gain in the last few months and rare vomiting attacks after eating.

Physical examination revealed a nontender, mobile, firm, protruding mass occupying the epigastric region. The lower abdomen was distended and bowel sounds were hyperactive. Vital signs were normal. Laboratory test results were notable for a hemoglobin concentration of 9.2 g/dL(N:11.5-18 g/dL) , MCV: 54.4 fL (N:76-96 fL) and a white blood cell count of 8400 x10⁹/L (N: 4000-11000x10⁹/L). Findings for electrolytes, amylase, and liver function were within normal range. Erythrocyte morphology was consistent with severe microcytic hypochromic anemia. Plain abdominal x-ray showed a prominent gastric outline (Fig.1). Ultrasound of the abdomen showed a large intragastric mass with acoustic shadows, and computed tomography scan showed a large solid mass in a distended stomach (Fig. 2) and dilated small intestinal loops (Fig. 3). The mass filled the gastric fundus and antrum. The diagnosis was gastric bezoar.

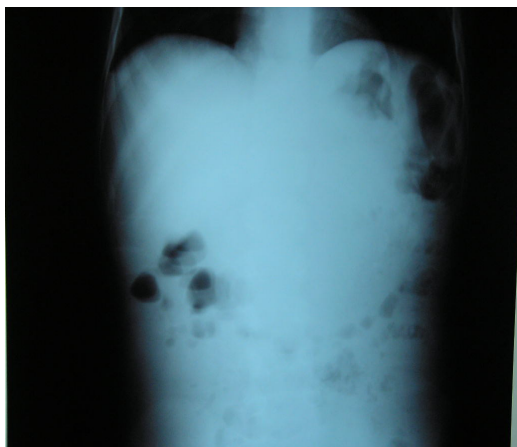


Figure 1: Plain radiograph showing prominent gastric outline.

Exploratory laparotomy was performed through an upper midline abdominal incision. An intraluminal, smoothly contoured, mass was found occupying the bulk of the stomach. A longitudinal 5-cm gastrotomy was made on the anterior surface of the corpus of the stomach (Fig. 4), and a contiguous trichobezoar cast of the stomach and duodenum was extracted (Fig.5). Moderate gastritis was noted along the lesser curve but no apparent gastric ulceration. There were no daughter bezoars and no extension of the bezoar into the duodenum.

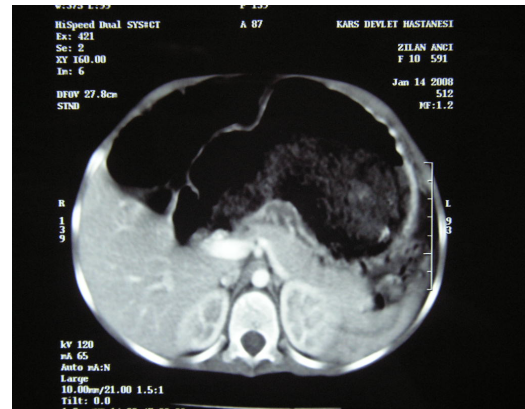


Figure 2: Axial computed tomography scan showing an amorphous foreign body in the stomach, nearly filling the gastric lumen.

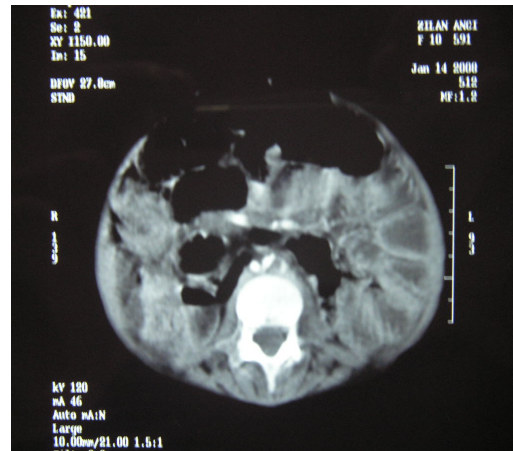


Figure 3: Axial computed tomography scan showing dilated intestinal loops.

The patient made a good postoperative recovery, without surgical complications. She was referred to the child guidance clinic for psychological support.

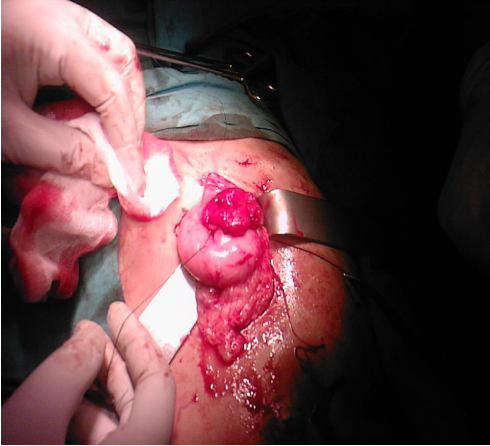


Figure 4: Gastrostomy section.

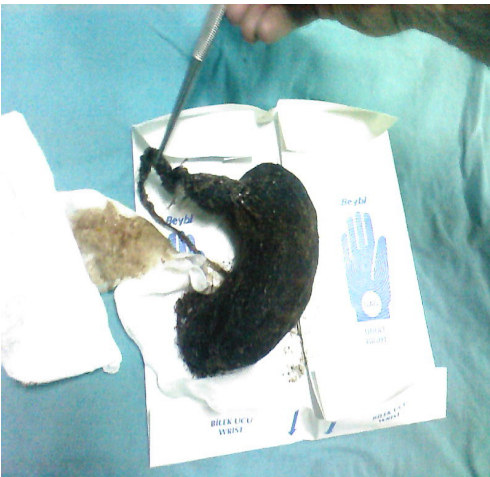

Figure 5: Extracted intestinal trichobezoar.

Summary and Discussion

Trichobezoars grow slowly over many years and form a cast in the shape of the stomach, sometimes extending to the small bowel [2]. They usually do not cause symptoms until they reach a large size. Large bezoars are palpable in 88% of cases. They are mobile and well-defined in 90% of cases, and sometimes indentable (Lamerton's sign) [6]. Trichobezoars may cause a number of complications, including gastritis leading to occult blood loss and secondary anaemia. Ten percent of patients have ulceration; perforating in about 30% of them [7]. Obstruction, hemorrhage, and intussusception have been recorded. The duration of the symptoms varies and is determined by the degree of change in the physiology of the gastroduodenum and the presence or absence of other complications [8].

Findings on plain x-ray film are similar to those in the present case. Ultrasound shows highly echogenic areas, with the mass casting a very intense sonic shadow [9]. Computed tomography reveals a well-defined intraluminal mass with interspersed gas. There may be dilated intestinal loops [10].

The present case stresses the possibility of gastric trichobezoar in young children who present with chronic anemia and anorexia. Clinicians should consider gastric trichobezoar in the differential diagnosis of small bowel obstruction.

References

1. De Backey M, Ochsner A. Bezoars and concretions. *Surgery*. 1938;4:934-963.
2. Andrus CH, Ponsky JL. Bezoar: classification, pathophysiology and treatment. *Am J Gastroenterol*. 1988;83:476-478.
3. Phillips MR, Zaheer S, Drugas GT. Gastric trichobezoar: case report and literature review. *Mayo Clin Proc*. 1998;73:653-656.
4. Konen O, Rathaus V, Shapiro M. Unsuspected trichobezoar in a child with short hair. *Am J Roentgenol*. 2001;176:258-259.
5. Kaushik NK, Sharma YP, Negi A, Jaswal A. Images – gastric trichobezoar. *Indian J Radiol Imaging*. 1999;9:137-139.
6. Lamerton AJ. Trichobezoar: two case reports - A new physical sign. *Am J Gastroenterol*. 1984;79:354-356.
7. Taylor TV, Torrance BH. Trichobezoar presenting as an unusual mass, *J R Coll Surg Edinb*. 1975;20(2):128-130.
8. Nawalkha PL, Mehta MC. Trichobezoar (a case report). *J Assoc Physicians India*. 1972;20(4):339-341.
9. Sood AK, Bahl L, Kaushal BK. Childhood trichobezoar. *Indian J Paediatr*. 2000;67(5):390-391.

10. O' Sullivan MJ, McGreal G, Walsh JG. Trichobezoar. J R Soc Med. 2001;94 (2):68-70.

Competing Interests: None declared.

Funding: None declared.

This manuscript has been peer reviewed

Correspondence:

Kasım çağlayan MD
Kars Devlet Hastanesi Genel cerrahi kliniği
036100
Kars, Turkey.
Tel: +90 474-2125012
e-mail: kasimcaglayan@hotmail.com