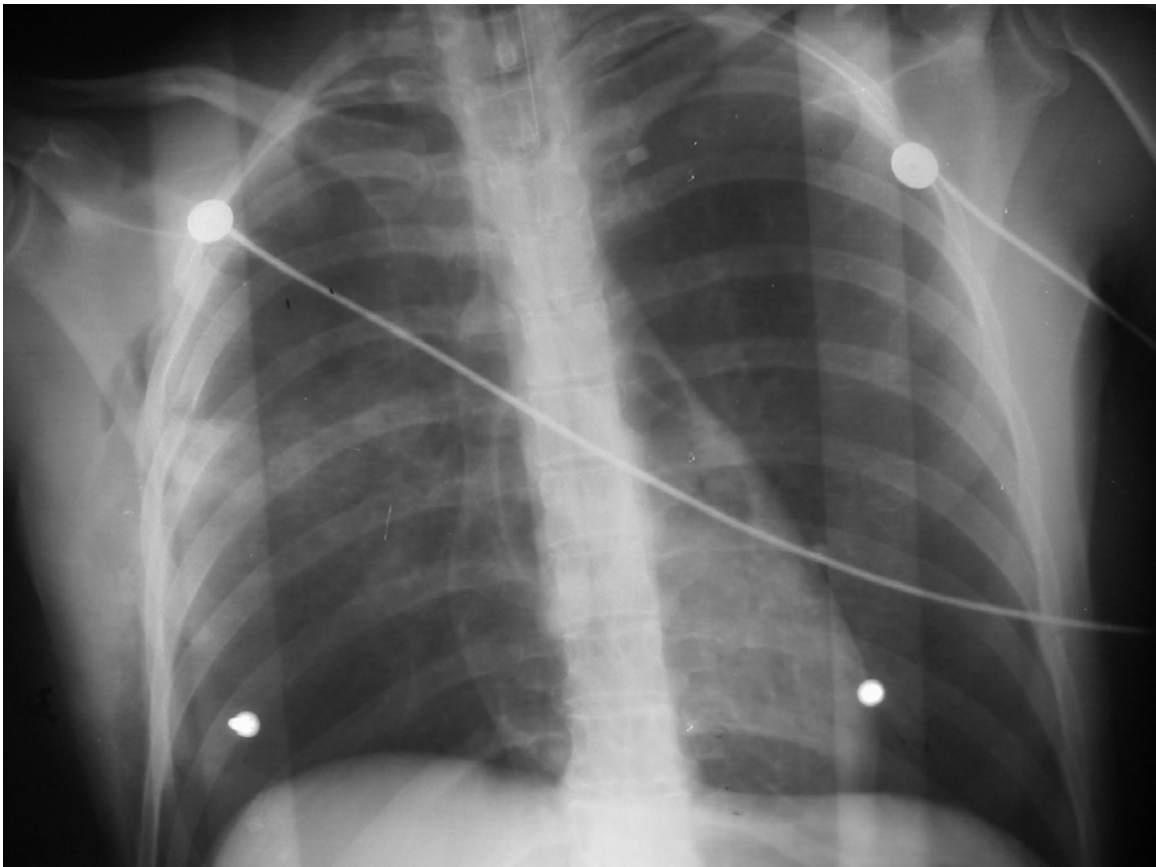

Radiology Challenge: The Sudden Death

Gelareh Zargaraff, MD[^] Michael I. Zucker, MD^{*},

^{*} MZ: Professor, Division of Radiology, UCLA

[^] GZ: Division of Emergency Medicine, UCLA



Case:

The patient is a 30 year-old female brought in by ambulance to the Emergency Department from a high speed motor vehicle accident. The patient was a restrained driver that was hit by a truck on her side of the vehicle. There was significant passenger space intrusion requiring extrication. The patient was found unconscious at the scene with an unobtainable blood pressure and minimally palpable pulse. There were no signs of

obvious head or thoracoabdominal trauma and no visible bleeding. On arrival to the ED, the patient was aggressively resuscitated and intubated. Shortly after intubation, the patient arrested and lost all her vital signs and was declared deceased 7 minutes after having arrived in the ED. A portable chest x-ray was obtained prior to intubation. Based on the below chest x-ray, what was the most likely cause of this woman's death?

Answer:

This patient has multiple systemic venous air emboli which ultimately resulted in her death. These are visible as areas of hyperlucency in the superior vena cava, right atrium and right ventricle. Although it is not certain as to how air was introduced into the venous system, it is likely that the trauma she sustained resulted in communication between the lungs and the cardiovascular system. Lacerations of lung parenchyma, air passages, and blood vessels are a few examples of how air can enter the venous circulation (1, 2). Depending on the rate and volume of air introduced into the venous system, certain venous air emboli can result in immediate hemodynamic collapse and death. It is this fistula formation that results in introduction of massive quantities of air and subsequent cardiopulmonary arrest shortly after intubation. This occurs as air introduced into the venous circulation results in obstruction of the pulmonary outflow tract and results in subsequent development of pulmonary hypertension, right ventricular strain and eventual cardiac failure with hemodynamic collapse (3). Air embolized to the coronary and cerebral vessels can also have devastating effects. As little as 2 milliliters of air in the cerebral vessels can be fatal and as little as 1-2 milliliters of air in the coronary vessels can cause severe ischemia (1).

Systemic venous air embolism (SVAE), also known as pulmonary air embolism, after blunt trauma is a finding that has been underreported and under recognized. Despite the scarcity of literature, all emergency physicians should consider this when treating trauma patients. Based on a few studies, SVAE has been found in 4 to 14% of patients with thoracic trauma. Of which, one third has been due to blunt trauma and two thirds due to penetrating trauma (1,4). The classic recognized cause of SVAE has been seen in the context of decompression illness in divers, aviators, and astronauts (5). The most common cause of SVAE has been iatrogenic. The most common surgeries complicated by SVAE are neurosurgical and otolaryngological interventions where mild or clinically silent systemic emboli are found in 10-80% of cases (6). Other reported causes of SVAE include lung needle biopsy, cardiac surgery, cardiopulmonary bypass, arterial and venous instrumentation, laparoscopy, and chest operations (1). The placement of central venous catheters, including

central lines or pulmonary artery catheters, have also been found to result in air embolism formation (3). Emboli have been found to occur during the insertion, maintenance and removal of these lines. Thus, when working with such lines, it is important to recognize signs and symptoms of SVAE.

The clinical presentation of major systemic air emboli include hemodynamic collapse and focal neurological changes, seizures, and other CNS dysfunction in absence of head injury. Prior to intubation, patients may have severe dyspnea and hemoptysis with a sense of impending doom. A preliminary diagnosis of SVAE can be made if patients are found to develop circulatory arrest immediately after intubation and positive pressure ventilation. As seen with this case, chest radiography can be helpful in the initial diagnosis (compare this to the normal chest x-ray below). Chest CT could also indicate intracardiac or intravascular air but this has never been reported in a live person (1). In less severe cases, transesophageal echocardiography has served as a reliable tool for detecting gas bubbles as small as 2 micrometers in diameter (1,6,7). Precordial ultrasound doppler has also been found to detect as little as 0.12 ml of air in the venous circulation (1, 6). In a surgically monitored situation, a lowering of the end-tidal carbon dioxide can be an indicator of the presence of SVAE (6).

Management of post-traumatic patients with possible SVAE is extremely difficult. It is preferable not to intubate patients who are able to maintain their airway. In patients who have a single lung injury, lung isolation techniques should be attempted to stop the flow of air into the circulation through the injured lung and preferentially oxygenate the noninjured lung. Patients requiring intubation should be kept on the lowest possible ventilatory volumes and pressures. Patients should receive continuous IV hydration with normal saline to help increase right atrial pressure and reduce the right to left pressure gradient (6,1). Patients should be kept supine at all times and placed on oxygen to help dislodge nitrogen from the larger gas bubbles and enhance their break down. Hyperbaric oxygen therapy has proved beneficial for patients with CNS emboli, by often reversing the neurological deficits. All patients with suspected SVAE should avoid nitrous oxide exposure as this has been shown to increase the size of the air

bubbles in vivo (1,7). In surgical cases or more controlled environments, the use of right atrial catheters to aspirate air is encouraged (5,6). If all these interventions prove unsuccessful, thoracotomy with hilar clamping may be helpful, but this remains controversial (1).

Competing Interest: None Declared

Funding: None Declared.

This article has been peer reviewed.

References:

- (1) Ho A, Ling E. Systemic air embolism after lung trauma. *Anesthesiology* 1999; 90: 564-75.
- (2) Harris J, Harris W. *The radiology of emergency medicine* 4th ed. Philadelphia: Lippincott Williams & Wilkins, 2000.
- (3) Orebaugh, SL. Venous air embolism: clinical and experimental considerations. *Crit Care Med* 1992; 20: 1169.
- (4) Trunkey D. Initial treatment of patients with extensive trauma. *N Eng J Med* 1991; 324: 1259-63.
- (5) Souders JE. Pulmonary air embolism. *J Clin Monit Comput.* 2000;16: 375-83.
- (6) Palmon SC, Moore LE, Lundberg J, Toung T. Venous air embolism: a review. *J Clin Anesth.* 1997;9: 251-7.
- (7) Muth CM, Shank ES. Gas embolism. *N Eng J Med* 2000; 342: 476-482.

Correspondence to:

Dr. Gelareh Zargaraff
Dept of Emergency Medicine,
UCLA Medical Center,
Los-Angeles, California , USA

Email: zargaraf@ucla.edu