

# Transient Torsades de Pointes after Adenosine

**Michael J.  
Drescher, MD**

Department of Emergency  
Medicine Sheba Medical  
Center Tel Hashomer,  
Israel and Division of  
Emergency Medicine  
University of  
Connecticut/Hartford  
Hospital Hartford  
Connecticut

**Richard  
Mendelssohn, MD**

Division of Emergency  
Medicine University of  
Connecticut/Hartford  
Hospital Hartford  
Connecticut

**Correspondence:**

**Michael J Drescher, MD**  
Department of Emergency  
Medicine  
Sheba Medical Center  
Tel Hashomer, Israel  
Email: mdreschermd@yahoo.com  
Tel: 058-547105  
Fax: 03 530 2055

## Transient Torsades de Pointes After Adenosine

Paroxysmal supraventricular tachycardia is a common presentation to the emergency department. While SVT is usually not life threatening, patients are often symptomatic and rapid conversion to normal sinus rhythm is desirable. Adenosine has become the standard of care in converting paroxysmal supraventricular tachycardia, including that associated with bypass tracts such as Wolff-Parkinson-White Syndrome, to normal sinus rhythm (1). While adenosine is not usually effective in converting rhythms other than PSVT, it may be useful in the diagnosis of underlying rhythms via a transient slowing of ventricular response immediately following administration.

Adverse effects of adenosine administration are numerous but generally self-limited due to its short half-life. At the time of conversion to normal sinus rhythm, a multitude of new rhythms may appear. Clinical trials have shown that various transient arrhythmias may be seen in approximately half of patients following an adenosine bolus (1). Most often these transient arrhythmias are premature ventricular contractions, atrial premature contractions, sinus bradycardia, and various degrees of AV block. By decreasing conduction through the AV node, adenosine may induce a transient first, second, or third degree heart block. The atrioventricular block induced by adenosine may allow for the development of bradycardia induced polymorphic ventricular tachycardia (2). Polymorphic ventricular tachycardia was originally described as a rapid ventricular rhythm with a typical undulating "twisting about a point" morphology, a prolonged QT interval and a T wave that does not return to the isoelectric line. Herein we report a case of transient torsades de pointes induced by adenosine, and discuss the rare complications of adenosine use in the treatment of arrhythmia.

## Case Report

A 57-year-old man called EMS after experiencing palpitations associated with light-headedness for two hours. He initially had no other symptoms during this episode. He further denied a history of similar episodes, past medical or surgical history or family history of cardiac disease. There were no medications, allergies, or illicit drug abuse. The patient did admit to consuming 8-10 cups of espresso during the day, and further referred to increasing amounts of job related stress.

During ground transport the patient started to complain about difficulty breathing, becoming diaphoretic and pale. At this time the patient remained hemodynamically stable with a blood pressure of 140/98. The monitor revealed a narrow complex tachycardia at a rate of 240 beats per minute. EMS personnel attempted vagal maneuvers without success (**figure 1**). IV access was obtained and 6 mg adenosine was given as a bolus rapidly followed by saline flush. Without any change on the monitor, a second bolus of 12 mg adenosine was given rapidly followed by saline flush.

Prior to conversion to normal sinus rhythm, there was an intervening period of 4 seconds where the patient was in torsades de pointes (**figure 2**). It should be noted that the patient did not develop the expected AV block prior to entering polymorphic ventricular tachycardia. Once in normal sinus rhythm the patient's color improved and he stated that he "felt a lot better." On arrival at our facility, a 12 lead ECG revealed normal sinus rhythm with no evidence of ischemic changes and no evidence of prolonged QT interval (QTc 415 ms) (**figure 3**). The serum potassium level measured 3.8 mEq/L; neither serum magnesium nor calcium levels were obtained.

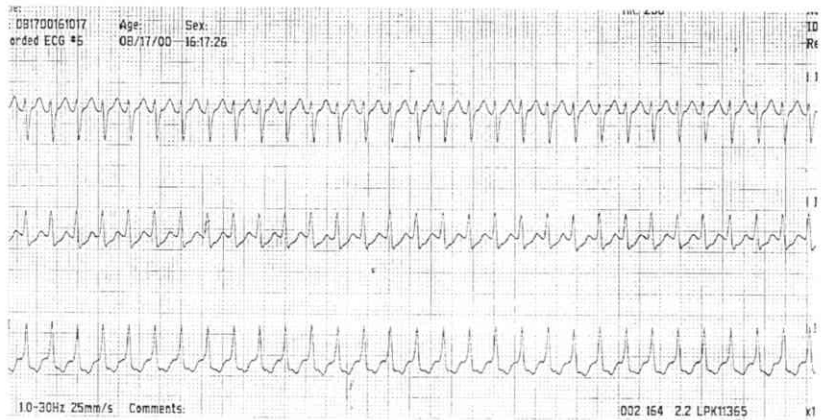


figure 1

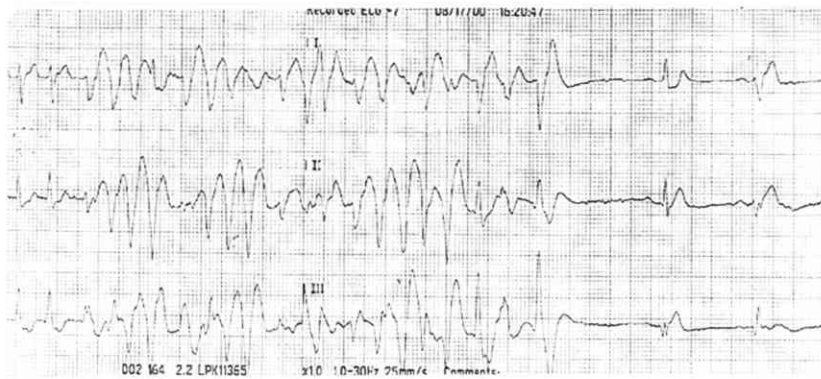


figure 2

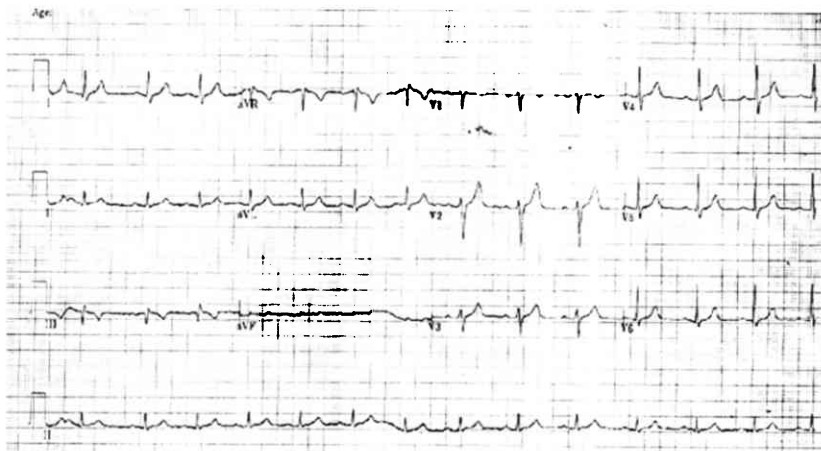


figure 3

**Discussion**

Adenosine has become the standard treatment of stable paroxysmal supraventricular tachycardia. Adenosine exerts its action by producing transient hyper polarization of the sinus node and AV nodal cell membranes via adenosine receptors, reducing cell activity. In addition it has an indirect antiadrenergic action via several mechanisms (3). Through these actions, adenosine produces a transient atrioventricular nodal block and sinus arrest when injected as an intravenous bolus. It commonly produces subjective symptoms, most commonly chest discomfort, dyspnea, and flushing. Arrhythmias may recur in a small number of patients.

Pauses, sinus bradycardia and transient asystole are often seen after adenosine, and are usually brief and clinically insignificant. Patients with known sick sinus syndrome may be more susceptible to prolonged sinus failure after treatment with adenosine. It is common to see premature atrial and ventricular beats after adenosine administration (3). Torsades de Pointes appears to be a rare phenomenon after use of adenosine. We discovered seven (2,4-8) prior cases reported in the literature.

While the effectiveness and safety profile of adenosine have made it the drug of choice for the treatment of supraventricular tachycardia, there are reports of deleterious effects following the use of adenosine. When given to patients with atrial flutter adenosine may "unmask" the flutter waves by increasing the AV block. However, there are reported cases where adenosine given during atrial flutter has caused various life threatening alterations in heart rate. These include the increase of ventricular response, high-grade AV block, prolonged asystole, and torsades de pointes (4,9). There are also cases of prehospital death associated with adenosine (10) in two cases when given in the presence of atrial fibrillation (11).

Prolonged QT syndrome, whether congenital or acquired, is associated with bradycardia-induced polymorphic ventricular tachycardia. A number of case reports describe adenosine-induced torsades in patients with prolonged QT intervals (5). A recent prospective study of administration of Adenosine in the ED in 160 patients showed non-sustained VT in 5% of cases, with no adverse outcome. (12)

The effects of adenosine are antagonized by methylxanthines such as caffeine and theophylline. In their presence larger doses of adenosine may be required to obtain normal sinus rhythm. While many physicians commonly use escalating doses of adenosine per ACLS guidelines, the excessive espresso consumption of our patient may account for the requisite 12 mg before successful conversion.

Smally has recently recommended that patients be instructed in 'cough CPR' prior to administration of Adenosine. This technique, by which patients are taught to cough deeply during the period of asystole or bradycardia, is said to produce enough cardiac output to avoid syncope and other hypotensive phenomena (13). However it has not been prospectively studied in this setting.

While generally safe and effective, adenosine should always be given by a vigilant practitioner with appropriate monitoring and resuscitation skills and equipment at hand.

#### References

1. Physician Desk Reference Online. [http://www.pdr.net/display.jsp?url=30800100.htm&productname=Adenocard Injection](http://www.pdr.net/display.jsp?url=30800100.htm&productname=Adenocard+Injection)
2. Romer M, Candinas R. Adenosine induced non-sustained polymorphic ventricular tachycardia. *European Heart Journal* 1994; 15:281-2
3. Wilbur SL, Marchlinski FE. Adenosine as an antiarrhythmic agent. *Am J Cardiol* 1997;79(12A):30-37
4. Brodsky MA, Hwang C, Hunter D, Peng-Sheng C, et al. Life threatening alterations in heart rate after the use of adenosine in atrial flutter. *American Heart Journal* 1995;130(3):564-71
5. Wesley RC, Turnquest P. Torsades de pointes after intravenous adenosine in the presence of prolonged QT syndrome. *American Heart Journal* 1992;123(3):794-96.
6. Harrington GR, Froelich EG. Adenosine induced torsades de pointes. *Chest* 1993;103:1299-1301
7. Smith JR, Goldberger JJ, Kadish AH. Adenosine induced polymorphic ventricular tachycardia in adults without structural heart disease. *Pacing & Clinical Electrophysiology* 1997;20(3 Pt 1):743-5
8. Frank R, Marty H. Polymorphic ventricular tachycardia after intravenous adenosine. *Journal Suisse de Medecine*. 2000;130(42):1576
9. Ben Sorek ESW, Wiesel J. Ventricular Fibrillation following adenosine administration. *Arch Intern Med* 1993;153:2701-2702
10. Christopher M, Key CB, Persse DE. Refractory asystole and death following the prehospital administration of adenosine. *Prehospital Emergency Care*. 2000;4(2):196-8
11. Haynes BE. Two deaths after prehospital use of adenosine. *Journal of Emergency Medicine*. 2001; 21(2):151-4.
12. Camaiti A, Pieralli F, Olivotto I, Grifoni S, et al. Prospective evaluation of adenosine-induced proarrhythmia in the emergency room. *European Journal of Emergency Medicine* 2001;8(2):99-105
13. Smally AJ. Preventing complications of adenosine administration. *Annals of Emergency Medicine* 2002;39(3):347-8