

## Post-Traumatic Perforated Appendicitis: A Case Report

Sumer A MD<sup>1</sup>, Caglayan K MD<sup>2</sup>, Altinli E MD<sup>3</sup> and Uurlu M MD<sup>2</sup>

<sup>1</sup>Department of General Surgery, Kas State Hospital, Antalya, Turkey

<sup>2</sup>Department of General Surgery, Kars State Hospital, Kars, Turkey

<sup>3</sup>Second General Surgery Unit, Haydarpaşa Numune Training and Research Hospital, Istanbul, Turkey

### Abstract

Acute appendicitis and blunt abdominal trauma are common surgical emergencies. The etiology and pathophysiology of appendicitis have been well investigated. However, the occasional cases of co-existent appendicitis and blunt abdominal trauma raise questions regarding a possible cause/effect relationship. We describe a child who presented with abdominal pain from blunt abdominal trauma caused by his fall from a height. A perforated appendicitis was detected during surgery and removed. We suggest that the diagnosis of appendicitis should be considered in some patients with blunt abdominal trauma.

**MeSH Words:** Abdominal trauma, appendicitis

### Introduction

Acute appendicitis and blunt abdominal trauma are very common surgical conditions. Although the exact mechanisms underlying acute appendicitis are still obscure, it is likely that luminal obstruction by external (lymphoid hyperplasia) or internal (fecal material, appendicoliths) compression plays a key pathogenic role. Less common, indirect, factors include emotional stress, leukemia, and blunt abdominal trauma [1-4]. However, trauma as a direct cause of luminal obstruction and consequent appendicitis has only been alluded to anecdotally. The occasional cases of co-existent appendicitis and blunt abdominal trauma have

raised questions regarding their cause/effect relationship [5].

We describe a child who presented to the Emergency Department (ED) with abdominal pain due to blunt abdominal trauma caused by a fall and was found to have a perforated appendix at surgery.

### Case report

A 4-year-old boy was brought to the ED two days after falling from a 3-meter height. On physical examination, blood pressure was 100/60 mmHg and pulse rate was 124 beats/min. No signs of trauma were visible. Local examination

of the abdomen revealed tenderness, rigidity, and muscular defense. Axillary temperature was 38°C and rectal temperature, 38.9°C. Blood analysis yielded hemoglobin 0.2 g/dl, hematocrit 30.9%, and white blood cell count 6900/mm<sup>3</sup>. Findings on urinalysis were normal. Plain x-rays of the abdomen and chest were inconclusive. Abdominal ultrasound scan showed a large amount of free fluid. No other abnormalities were noted. Abdominal computerized tomography (CT) scan showed a large amount of free fluid in the dilated bowel and periappendicular area (Figure 1). Because of a suspicion of acute abdomen, laparotomy was performed through a minimal midline incision. Exploration revealed about 500 cc of purulent intra-abdominal fluid and a perforated appendix (Figures 2,3). There was no evidence of a fecalith, solid organ injury, bruising, or mesenteric hematoma. Meckel's diverticulum was absent. Treatment consisted of appendectomy. The postoperative course was uneventful.

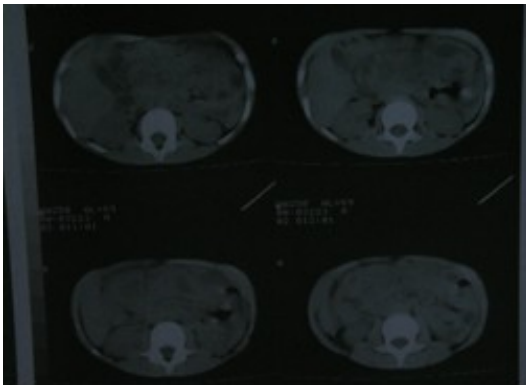


Figure 1. CT view of intra-abdominal fluid collection.

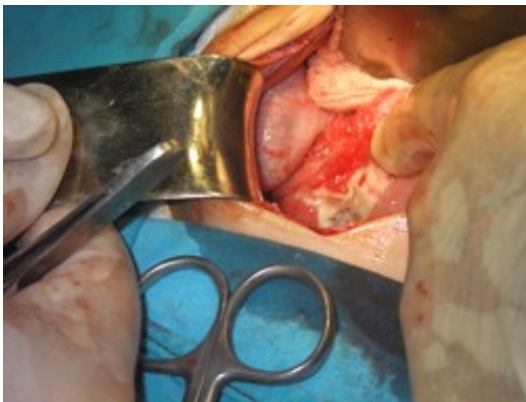

Figure 2. View of the right lower quadrant during surgery.

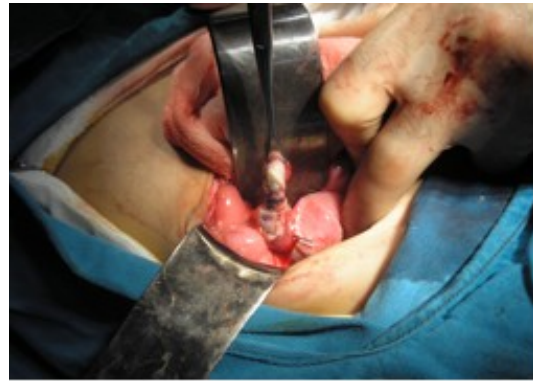

Figure 3: Panoramic view of the perforated appendicitis during surgery.

### Discussion

The lifetime rate of appendectomy is 12% for men and 25% for women. Approximately 7% of all people undergo appendectomy for acute appendicitis. The incidence peaks in the second and fourth decades of life [3,6].

Obstruction of the lumen is the dominant casual factor in acute appendicitis. Fecaliths are the usual reason for the obstruction, followed by hypertrophy of the lymphoid tissue, inspissated barium from previous x-ray studies, tumors, vegetable and fruit seeds, and intestinal parasites. Rare, nonobstructive causes of appendicitis include endometriosis, leukemia, and emotional stress. Some authors suggested that mucosal and submucosal inflammation secondary to bacterial invasion of the appendiceal lymphoid tissue may in some cases progress to appendicitis [2,6]. Findings of an increased rate of appendicitis in Japanese tourists exposed to Greek food led to the speculation that acute appendicitis may in rare instances be associated with dietary modifications [7,8].

The role of blunt abdominal trauma as a direct cause of appendiceal obstruction is unclear. Some authors claimed that given the high frequency of occurrence of both acute appendicitis and blunt abdominal trauma in the general population, their co-existence is likely coincidental [3]. Others, however, suggested that blunt abdominal trauma may be another etiological factor in appendicitis [2]. Hennington et al.[5] and Ciftci et al. [9] described cases in which blunt abdominal trauma apparently induced appendiceal edema, inflammation, or hyperplasia of the intrinsic

lymphoid tissues, resulting in obstruction of the appendiceal lumen and acute appendicitis. Serour et al. [10] proposed that direct appendiceal injury generally occurs concomitantly with other intra-abdominal organ injuries, but the appendix is very rarely affected by direct trauma because of its high mobility and very small dimensions.

The indirect induction of appendicitis by blunt abdominal trauma is even more obscure. The well-known increase in intra-abdominal pressure that occurs in response to blunt abdominal trauma may be implicated in this phenomenon. The increased pressure is apparently due to the relative decrease in size of the abdominal cavity consequent to the post-traumatic conditions, namely, external compression, intraperitoneal bleeding or retroperitoneal hematoma, acute gastric dilatation, or intraperitoneal space-occupying free air [2].

There are no standard criteria for the diagnosis of acute appendicitis associated with abdominal trauma. Therefore, physicians require a high index of suspicion and careful analysis of the history and indirect clinical findings. We believe trauma should be considered among the causes of acute appendicitis under certain conditions: apparent absence of other etiologic factors of appendicitis; a recent (6-48 hours) history of trauma; lack of abdominal pain before the trauma; and clinical findings of ecchymosis, abdominal wall hematoma, injury to intra-abdominal organs, mesenteric injury, etc. [10,11]. In our case, although there were no intra-abdominal injuries to support a cause of blunt trauma, we failed to identify any other etiologic factor that could account for the perforated appendicitis. Our assumption was supported by the report of the boy's fall from a height 48 hours previously.

### Conclusions

In conclusion, appendicitis may occur consequent to blunt abdominal trauma in rare cases. In the patient described here, our assumption of a causative relationship was based on strong circumstantial evidence, although we had no definitive proof.

### References

1. Karavokyros I, Pikoulis E, Karamanakis P. A case of blunt abdominal trauma and posttraumatic acute appendicitis. *Ulus Travma Acil Cerrahi Derg* 2004; 10:60-62.
2. Etensel B, Yazici M, Gürsoy H, Ozkisacik S, Erkus M. The effect of blunt abdominal trauma on appendix vermiformis. *Emerg Med J* 2005; 22:874-877.
3. Tekin K, Ozek MC. Acute appendicitis after blunt abdominal trauma. *Ulus Travma Derg* 2001; 7:207-209.
4. Ditillo MF, Dziura JD, Rabinovici R. Is it safe to delay appendectomy in adults with acute appendicitis? *Ann Surg* 2006; 244:656-660.
5. Hennington MH, Tinsley EA Jr, Proctor HJ, Baker CC. Acute appendicitis following blunt abdominal trauma. Incidence or coincidence? *Ann Surg* 1991; 214:61-63.
6. Jaffe BM, Berger DH. The appendix. In: Brunicaudi FC, Andersen DK, Billiar TR, Dunn DL, Junter JG, Pollock RE, editors. *Schwartz's Principles of Surgery*, eighth edition. New York: McGraw-Hill, 2005;1119-1138.
7. Black J. Vegetable consumption and acute appendicitis. *Br Med J* 1986; 293:52.
8. Burkitt DP. The aetiology of appendicitis. *Br J Surg* 1971; 58:695-699.
9. Ciftci AO, Tanyel FC, Buyukpamukcu N, Hicsonmez A. Appendicitis after blunt abdominal trauma: cause or coincidence? *Eur J Pediatr Surg* 1996; 6:350-353.
10. Serour F, Efrati Y, Klin B, Shikar S, Weinberg M, Vinograd I. Acute appendicitis following abdominal trauma. *Arch Surg* 1996; 131:785-786.
11. Ramsook C. Traumatic appendicitis: Fact or fiction? *Pediatr Emerg Care* 2001; 17:264-266.

**Competing Interests:** None declared.

**Funding:** None declared.

This manuscript has been peer reviewed

**Correspondence:**

Aziz Sumer MD  
Kaş Devlet Hastanesi Başhekimlik  
07580, Kaş  
Antalya, Turkey.  
Phone: +90 05059257142,  
Fax: +90 2428361604,  
e-mail: [azizsumer2002@yahoo.com](mailto:azizsumer2002@yahoo.com)