

Radiology Update in Pediatric Emergency Medicine

Robert A. Belfer MD¹

¹ Children and Adolescent Rapid Emergency Services, Virtua Health System, Voorhees, New Jersey

Abstract

Significant advances in radiological techniques have led to improved care of ill and injured children in the Emergency Department. This work reviews the most recent findings on the still-controversial value of imaging for the diagnosis and treatment of acute scrotal and abdominal pain in the pediatric age group. The role of color Doppler ultrasound in the differential diagnosis of suspected testicular torsion is stressed, especially in low-risk patients, as are the diagnostic benefits of sonography in children with possible intussusception – where the yield of plain films is low -- provided that operator training is sound. The typical imaging pictures are described, and the place of imaging in the therapeutic armamentarium is weighed against other available modalities. In addition, the advantages and limitations of ultrasound and computed tomography in the diagnosis of suspected appendicitis are discussed, together with the possibility of their combined use.

MeSH Words: Imaging, intussusception, testicular torsion, appendicitis

Introduction

Over the last decade, pediatric emergency medicine has benefited from significant advances in radiology. The introduction of digital cross-sectional imaging, increased use of ultrasonography, and advent of telemedicine have all led to improved care of the ill or injured child. However, the utility and value of imaging in children with acute scrotal or abdominal pain are still controversial. This article reviews the latest ways that different imaging modalities can facilitate the diagnosis and treatment of children who present to the Emergency Department with acute scrotum, vomiting, intermittent abdominal

pain and currant jelly stool, and right lower quadrant pain.

I. The child with acute scrotal pain

Why is imaging important in the management of a child with an acute scrotum?

Testicular torsion afflicts 1 in every 125 males, almost all under the age of 20 years [1]. The diagnosis of testicular torsion in children with acute scrotum is important because it is a medical emergency. However, the clinical signs

of testicular torsion overlap with torsion of the testicular appendix, epididymo-orchitis and trauma. The differentiation of these conditions is imprecise, with a nearly 50% false-positive rate for the diagnosis of testicular torsion based solely on clinical findings, leading to often unnecessary surgical exploration [2]. Indeed, up to 70% of cases of acute scrotum are due to a pathology that does not require surgery [3-5].

The salvage rate of testicular torsion depends on its duration and degree. Treatment within the first 6 hours of onset of symptoms is associated with an almost 100% salvage rate; treatment within 6 to 12 hours, with a 70% salvage rate, and treatment within 12 to 24 hours, with a 20% rate [6]. In patients presenting early, imaging plays a critical role in determining whether exploratory surgery is necessary.

Is there a role for radionuclide imaging, i.e. nuclear scintigraphy, in testicular torsion?

Probably not. In the 1980s, nuclear medicine studies were considered more accurate than sonography for diagnosing and ruling out testicular torsion (Figure 1). However, owing to improvements in ultrasound (US) technology, this is no longer the case. Nuclear medicine studies are limited by lack of anatomic definition. They may also yield false-negative results in patients with testicular torsion because the hyperemic scrotal skin can take up atypical amounts of tracer. Torsion of less than 360 degrees can cause diminished blood flow which can be better detected by color Doppler sonography [7-9].

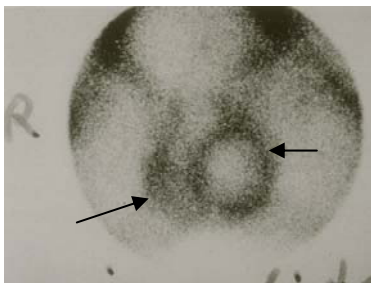


Figure 1: Radionuclide image showing normal blood flow to the left testicle (long arrow) with absent blood flow to the right one. Note the hyperemic ring around the left testicle indicating blood flow to the surrounding scrotal wall (short arrow).

Are gray scale US images useful in the acute evaluation of a painful scrotum?

Gray scale images are not specific for testicular torsion [10], and they may appear normal if the torsion has just occurred (Figure 2). At 4 to 6 hours after onset of torsion, gray scale images may reveal testicular swelling and decreased echogenicity; at 24 hours, they reveal a heterogeneous testicular echotexture secondary to vascular congestion, hemorrhage, and infarction [11].

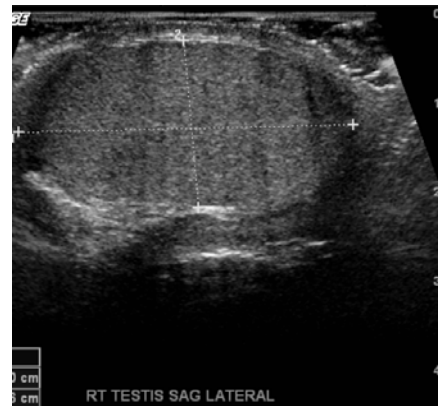

Figure 2: Grey scale ultrasound image of a normal-size right testicle.

How sensitive and specific is color Doppler US for diagnosing testicular torsion?

Color Doppler US is currently the preferred diagnostic imaging modality for testicular torsion because of the superior anatomic and functional detail it provides (Figure 3). Studies have shown that when the presence or absence of intratesticular flow was used as the only diagnostic criterion in children with painful scrotum, color Doppler US had an 86% sensitivity, 100% specificity, and 97% accuracy in the identification of torsion and ischemia [12].

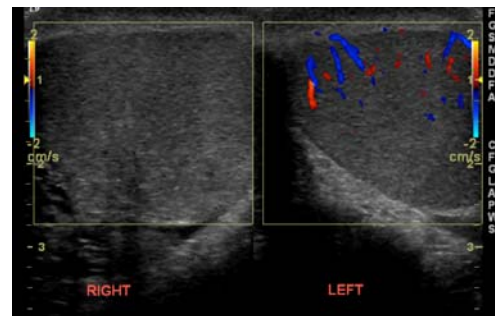


Figure 3: Color Doppler US scan showing blood flow to the left testicle but no blood flow to the right one.

Is the presence of Doppler flow to the testicle an “all or none phenomenon” in testicular torsion?

The sonographic picture in patients with testicular torsion varies by the degree of rotation of the spermatic cord. The most important finding is decreased testicular blood flow, which occurs when the cord twists 120°, or absent testicular blood flow, which occurs when the cord twists 720° [13,14].

Nevertheless, the presence of testicular flow does not necessarily exclude testicular torsion. When torsion is early or incomplete, some blood flow may be noted on the Doppler sonogram [15], resulting in a difference between the two sides. In these cases, Doppler arterial and venous waveform studies can facilitate diagnosis. Since the venous circulation, which is a low pressure system, is compromised first in the torsion process (Figures 4-6), early or partial torsion may yield absent venous waveforms while arterial waveforms are still present [16]. These findings warrant surgical intervention.

In cases of partial or complete spontaneous detorsion, Doppler US may show normal or even increased testicular blood flow [16].

What role does imaging play in the high-risk versus low-risk patient with testicular torsion?

Acute scrotum poses a diagnostic challenge for the emergency physician, urologist, and radiologist, since no single examination or laboratory finding provides a definitive diagnosis with 100% accuracy, short of surgical exploration. The need for a rapid diagnosis further complicates this situation, for while radiologic testing delays diagnosis, unnecessary surgical exploration is undesirable.

Therefore, if the clinical history and physical examination are highly suspicious for torsion, immediate testicular exploration should be performed, eliminating the expected delay of US examination [17, 18]. However, in most children, the clinical evaluation is not specific enough, and it is in this lower-risk group of children that color Doppler US examination of the scrotum is most useful.

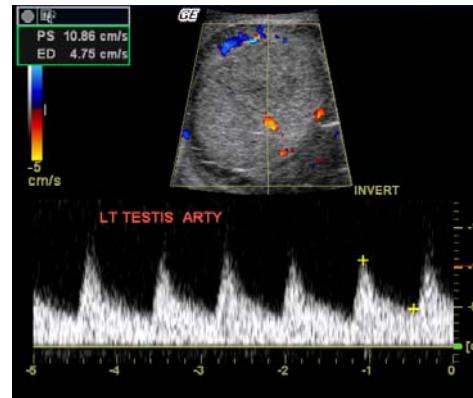


Figure 4: Color Doppler arterial waveforms revealing blood flow to the left testicle.

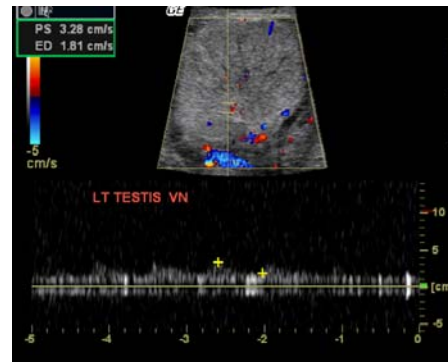


Figure 5: Color Doppler venous waveforms revealing blood flow to the left testicle.

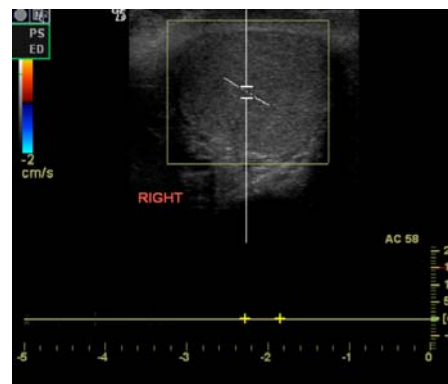


Figure 6: Color Doppler US scan revealing absence of blood flow to the right testicle.

II: The young child with vomiting, intermittent abdominal pain, and currant jelly stool

If there is a clinical suspicion of intussusception, should plain radiographs of the abdomen be obtained?

The yield of plain films in intussusception is low. Sargent et al. [19] and Bolin [20] reported a less than 50% correct identification of intussusception on plain radiographs. The characteristic radiographic signs include the meniscus sign and the target sign (Figures 7, 8) [19, 20]. Findings suggestive of intussusception are a soft tissue mass, absence of cecal gas and stool, and paucity of bowel gas [19, 21]. Air-fluid levels are noted almost as frequently in children with intussusception as in those without. Evidence of small bowel obstruction (Figure 9) or free intraperitoneal air in children with intussusception is rare [19].

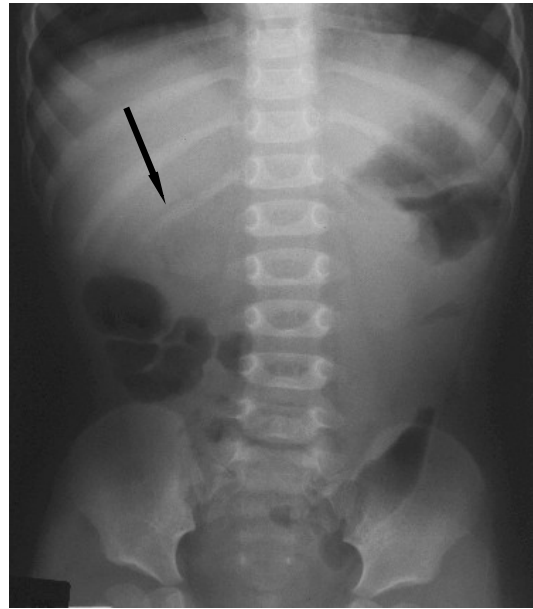


Figure 8: Plain abdominal film showing the target sign seen with intussusception.

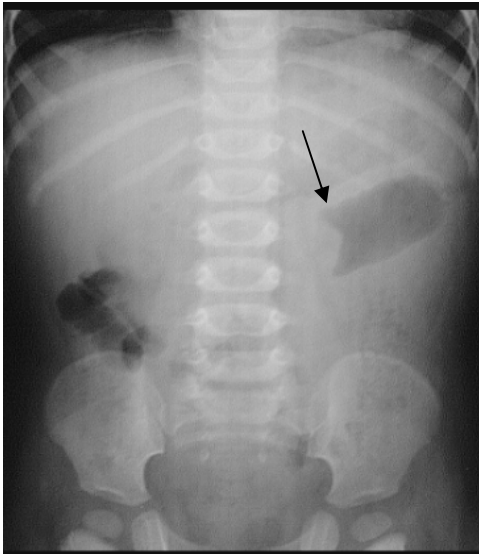


Figure 7: Plain abdominal film showing the meniscus sign seen with intussusception.

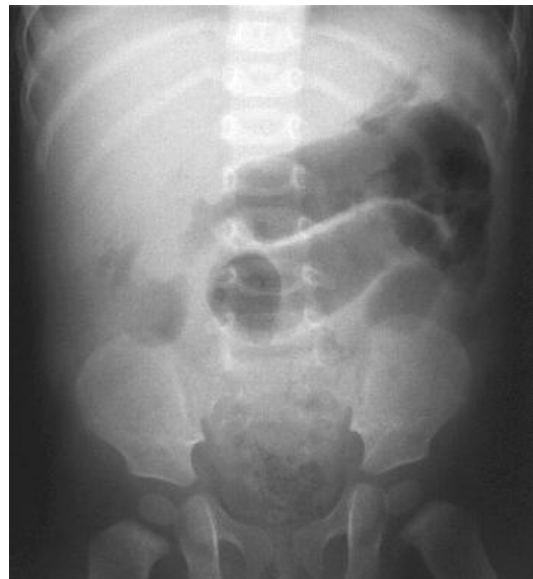

Figure 9: Plain abdominal film revealing evidence of early small bowel obstruction in a child with intussusception.

What are ultrasound findings of intussusception?

Intussusception has a characteristic sonographic appearance [24, 25]. Target or pseudokidney images are seen (Figures 10,11), with the intussusception usually located just deep to the abdominal wall, mostly on the right side of the abdomen.

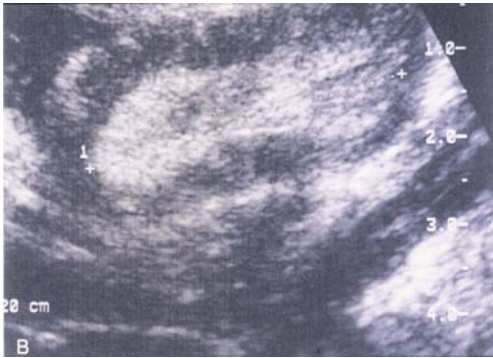

Figure 10: Ultrasound scan showing the "pseudo-kidney" appearance of the intussusception.

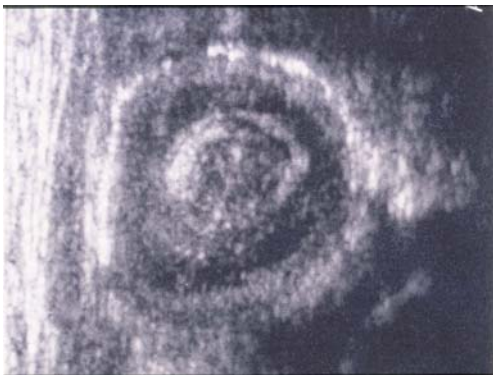

Figure 11: Ultrasound scan showing the target sign of the intussusception.

How easy or difficult is it for the radiologist to identify cases of intussusception using US?

The role of sonography in the diagnosis of intussusception is well established, with a sensitivity of 98% to 100% and a specificity of 88% to 100% [29]. However, the quality and interpretation of US images are definitely operator-dependent [26]. Although the literature suggests that sonographic recognition of intussusception requires some level of expertise on the part of the radiologist, several studies have shown that appropriate training may suffice [27,28]. Verschelden et al. [27] found that a 100% accuracy rate could be achieved by third- and fourth-year radiology residents who completed a 3-5-month training course in adult sonography. Daneman [28] reported a similarly high accuracy rate when sonographic studies were performed by pediatric radiology fellows who had completed 4 years of residency and were given practical, targeted training in the sonographic detection and evaluation of intussusception.

It has been suggested that sonography should be the initial imaging modality, with the enema examination reserved for therapeutic purposes [30]. In cases of negative findings for intussusception in young children, US may be useful in detecting other pathologic processes. Pracos et al. [31] reported a 4% detection rate of other intraabdominal diseases in such cases, including urinary tract pathology, torsion of ovarian cyst, and small bowel volvulus.

Is sonography more useful in older patients with intussusception who are more likely to have a pathologic lead point?

Sonography can be effective in identifying the presence of pathologic lead points, such as Meckel's diverticulum, duplication cysts, intestinal polyps, lymphoma, and intramural hematomas, which may be seen in children more than 3 years old [32]. In their review, Navarro et al. [3] reported sonographically depicted lead points in 23 of 35 patients (66%), whereas barium enema depicted the lead point in only 6 of 15 patients (40%), and air enema, in 3 of 28 patients (11%).

Has US been universally adopted for the evaluation of intussusception?

In many parts of the world, sonography has become the imaging modality of choice for the evaluation of children with suspected intussusception. Nevertheless, some radiologists and departments have been slow to implement it [26, 34, 35, 36] because of lack of expertise of the radiology staff, high cost, and low accessibility. In addition, some argue that contrast enema is performed for diagnosis, the physician can then simply continue with this modality to reduce the intussusception, if present [37].

Is there a role for US in reducing intussusception?

The use of sonography to guide hydrostatic reduction is most prevalent in the Eastern hemisphere and is increasing in Europe. The reduction rate is high (76%–95%), and the perforation rate, according to Riebel [37] and Rohrschneider [38], quite low (1 in 825 cases). The instilled fluid – either water, saline solution, or Hartmann solution -- is followed as it courses through the large bowel until it fills the terminal

ileum and distal small bowel and the intussusception is no longer visualized. The advantages of this procedure include no radiation exposure, high accuracy and reliability for monitoring the reduction process, visualization of all components of the intussusception (including the edematous ileocecal valve following reduction), and easier recognition of pathologic lead points and residual intussusception. The main disadvantage is the need for an available radiologist who is comfortable with the use of this modality for enema guidance.

Unfortunately, when air enemas are performed, the air prevents the passage of the US beam making it difficult for the operator to visualize the ileocecal valve; therefore, small residual ileoileal intussusceptions cannot be observed. Additionally, US is not amenable to the detection of a perforation-induced pneumoperitoneum [38].

For strictly DIAGNOSTIC reasons, is contrast enema still the study of choice?

Until the mid-1980s, barium enema examination was considered the gold standard for the diagnosis or exclusion of intussusception in many parts of the world. Many institutions still consider the contrast enema (with barium or air) as the quickest and most cost-effective method [39]. Several reasons are offered for its use: it is probably the least likely of the available means to miss a diagnosis of intussusception; it is well known to all radiologists; and once the diagnosis is made, therapy can be undertaken as part of the same procedure, in the same session [37].

What are some of the reasons why contrast enema may not be the diagnostic study of choice?

Contrast enema is an invasive procedure and also requires a small dose of radiation. In addition, it may not depict pathologic lead points as well as sonography, and in children found to be negative for intussusception, it may not identify other intra-abdominal pathology [33].

The clinician should consider these factors when deciding whether to use a contrast enema or sonography simply for diagnosis, especially in view of earlier reports of a more than 50% rate of negative findings for contrast enemas in

children with suspected intussusception [40, 41]. This high rate reflects the overlap of the clinical findings of intussusception with other acute abdominal conditions in children.

III: The child with right lower quadrant pain

What role does imaging play in the diagnosis of possible appendicitis?

Annually, 60,000–80,000 children are treated for appendicitis in the United States [42]. We know that the number of children with suspected appendicitis referred for imaging evaluation is much higher. In the past, radiology had little to offer other than the identification of appendicoliths on plain films or non-filling of the appendix on barium enema. However, advances in US and CT over the last 10 years have made imaging a key factor in the diagnosis of appendicitis in the ED in children with equivocal clinical findings. Nevertheless, while advocates of imaging cite improvements in diagnosis, reduced “negative” appendectomies, and better outcomes, others cite delays in diagnosis, greater expense, increased perforation rates, and greater costs without any demonstrable benefit to the patient.

Is there a role for plain abdominal films?

In select cases, abdominal films are useful for detecting fecaliths, localized ileus, scoliosis to the right (Figure 12), soft-tissue masses, and obliteration of the psoas margin.

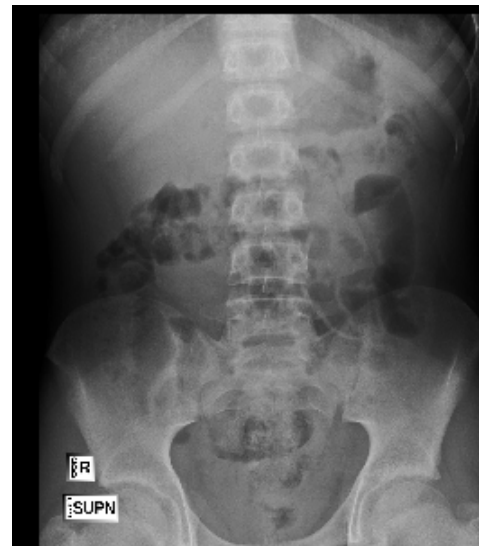

Figure 12: Splinting noted by slight curvature of the vertebral bodies to the right.

*How effective is appendiceal ultrasonography?
What are its advantages and limitations?*

Ultrasonography has been used in the evaluation of children with suspected appendicitis for the past decade. During that time, 14 published studies including nearly 10,000 patients reported acceptable specificity (88%–99%) and accuracy (82%–99%), although the range of sensitivity was wide (50%–100%) [44].

The advantages of this modality include portability, noninvasiveness, rapid performance, and absence of radiation exposure. It is preferred in the evaluation of thin adolescent females in whom the differential diagnosis includes tubo-ovarian pathology. Limitations include high user dependence and only rare visualization of the normal appendix. Visualization rates vary widely in the literature, from a high of 98% to a low of 22% [45]. US also has limited use in obese adolescents.

What are the typical ultrasonography findings in acute appendicitis?

US findings consistent with acute appendicitis include a distended, painful and noncompressible fluid-filled tubular structure measuring more than 6 mm in diameter. Other findings are an appendicolith, which appears as an echogenic focus with acoustic shadowing, and pericecal or periappendiceal fluid

In cases of nonperforated appendicitis, color Doppler US demonstrates peripheral wall hyperemia reflecting inflammatory hyperperfusion. Color flow may be absent in gangrenous appendicitis or early inflammation. In cases of appendiceal perforation, color Doppler findings include hyperemia in the periappendiceal soft tissue or within a well-defined abscess [44].

What is the role of abdominal CT? What are its advantages and limitations?

Since 1999, 9 studies including a total of 1425 patients have been performed to evaluate the role of CT in the diagnosis of pediatric appendicitis. CT imaging was found to have a 94-100% sensitivity, 89%–100% specificity, and 93%–99% accuracy, despite the wide variability in techniques used. There remains considerable controversy in the literature regarding the use of

oral, rectal, or intravenous contrast agents and possible limitations on the body area to be scanned [44].

Advantages of CT imaging in this setting include potentially improved patient management, greater comfort to clinician and patient, less operator dependence than for US, more confident visualization of the appendix, and better delineation of the extent of phlegmon and abscess in complicated cases (Figures 13, 14).

Furthermore, CT is readily available and reproducible. Disadvantages include potential risks of contrast medium and ionizing radiation exposure

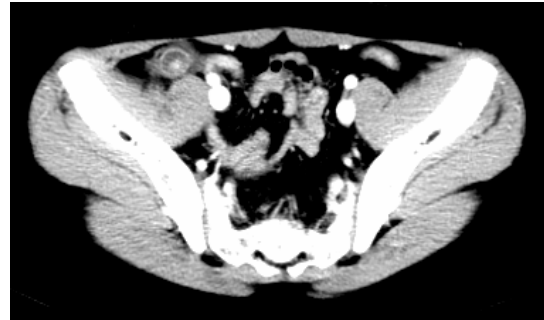

Figure 13: CT scan showing thickened wall of the fluid-filled appendix. An appendicolith is also present.

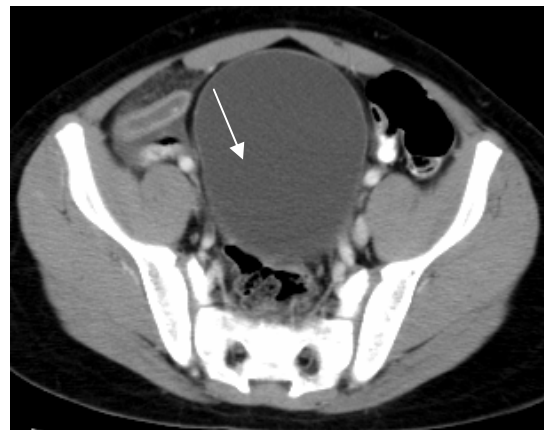


Figure 14: CT scan showing a fusiform, fluid-filled appendix.

Is the radiation risk of CT scans an important issue?

Owing to the risk of ionizing radiation, childhood CT is not innocuous. Children are 10 times more sensitive than adults to radiation-induced cancer. In the United States, approximately 600,000 abdominal and head CT examinations are performed annually in children

under the age of 15 years. Researchers estimate that roughly 500 children will ultimately die from cancer attributable to CT radiation. Currently, the best estimate of the lifetime cancer mortality risk of radiation exposure in a single abdominal CT examination in a 1-year-old child is 1 in 550. [43]

This risk can potentially be lowered by reducing the dosage of the ionizing radiation in children. However, reduced dosage is also the major reason for limitation of the scanning field, which may result in a failure to include the appendix in the CT scan and, thereby, adversely affect the reader's ability to detect alternative conditions. Therefore, researchers recommend that if CT is going to be performed, it should be done with the lowest dose that provides the radiologist with the necessary diagnostic information [43].

For equivocal clinical cases, which imaging study is better—US or CT?

Taylor [44] claimed that an effective imaging protocol should include both US and CT. He suggested that US be performed initially (although omission of this step might be considered in obese children), and if the findings are inconclusive or fail to show the appendix, then contrast-enhanced CT should follow. Pena et al. [45] reported that this sequence of imaging had a combined sensitivity of 94%, specificity of 94%, positive predictive value of 90%, negative predictive value of 97%, and accuracy of 94%. In 22% of cases, the initial US examination provided enough information to forgo the CT evaluation and its attendant radiation and stresses.

Practically, however, the choice of imaging depends on the resources available in each institution, not the diagnostic accuracy. Imaging protocols that work in one clinical setting may not be amenable to others. In an academic environment with readily available pediatric radiology fellows and faculty, US followed by CT with intravenously and rectally administered contrast material is, indeed, a reasonable approach. Clinicians at each hospital should review their local experience with imaging and clinical outcomes to determine what radiology imaging pathways should be implemented when evaluating a child with right lower quadrant pain.

References

1. Rumack C, Wilson S, Charboneau W, Johnson J-A. Diagnostic Ultrasound, 3rd edition. St. Louis, MO: Mosby-Year Book, 2005; 874–877.
2. Dubinsky TJ, Chen P, Maklad N. Color-flow and power Doppler imaging of the testes. *World J Urol* 1998; 16:35-40.
3. Kass E, Stone K, Cacciarelli A, Mitchell B. Do all children with an acute scrotum require exploration? *J Urol* 1993; 150:667-669.
4. Cass A, Cass B, Veeraraghavan K. Immediate exploration of the unilateral acute scrotum in young male subjects. *J Urol* 1980; 124:829-832.
5. Lewis A, Bukowski T, Jarvis P, Wacksman J, Sheldon C. Evaluation of acute scrotum in the emergency department. *J Pediatr Surg* 1995; 30:277-282.
6. Patriquin HB, Yazbeck S, Trinh B, Jequier S, Burns PN, Grignon A, et al. Testicular torsion in infants and children: diagnosis with Doppler sonography. *Radiology* 1993; 188:781-785.
7. Dogra VS, Gottlieb RH, Oka M, Rubens DJ. Sonography of the scrotum. *Radiology* 2003; 227:18-36.
8. Allen TD, Elder JS. Shortcomings of color Doppler sonography in the diagnosis of testicular torsion. *J Urol* 1995; 154:1508-1510.
9. Middleton WD, Siegel BA, Melson GL, Yates CK, Andriole GL. Acute scrotal disorders: prospective comparison of color Doppler US and testicular scintigraphy. *Radiology* 1990; 177:177-181.
10. Blaivas M, Sierzenski P, Lambert M. Emergency evaluation of patients presenting with acute scrotum using bedside ultrasonography. *Acad Emerg Med* 2001; 8:90-93.
11. Horstman WG. Scrotal imaging. *Urol Clin North Am* 1997; 24:653-671.
12. Vasavada P. Ultrasound evaluation of acute abdominal emergencies in infants and children. *Radiol Clin North Am* 2004; 42:445-456.

-
13. Burks DD, Markey BJ, Burkhard TK, Balsara ZN, Haluszka MM, Canning DA. Suspected testicular torsion and ischemia: evaluation with color Doppler sonography. *Radiology* 1990; 175:815-821.
14. Blaivas M, Brannam L. Testicular ultrasound. *Emerg Med Clin North Am* 2004; 22(3):589-593.
15. Kalfa N, Veyrac C, Baud C, Couture A, Averous M, Galifer RB. Ultrasonography of the spermatic cord in children with testicular torsion impact on the surgical strategy. *J Urol* 2004; 172:1692-1695.
16. Dogra V, Bhatt S. Acute painful scrotum. *Radiol Clin North Am* 2004; 42(2):349-363.
17. Sanelli PC, Burke BJ, Lee L. Color and spectral Doppler sonography of partial torsion of the spermatic cord. *Am J Roentgenol* 1999; 172:49-51.
18. Kass EJ, Lundak B. The acute scrotum. *Pediatr Urol* 1997; 44:1251-1266.
19. Sargent MA, Babyn P, Alton DJ. Plain abdominal radiography in suspected intussusception: A reassessment. *Pediatr Radiol* 1994; 24:17-20. Bolin H. Conventional roentgenography in diagnosis of intussusception in children. *Acta Radiol Diagn* 1964; 2:32-40.
20. Bolin H. Conventional roentgenography in diagnosis of intussusception in children. *Acta Radiol Diagn* 1964; 2:32-40.
21. Lee JM, Kim H, Byun JY, Lee HG, Kim CY, Shinn KS, Bahk YW. Intussusception: characteristic radiolucencies on the abdominal radiograph. *Pediatr Radiol* 1994; 24:293-295.
22. Fiorella DJ, Donnelly LF. Frequency of right lower quadrant position of the sigmoid colon in infants and young children. *Radiology* 2001; 219:91-94.
23. Eklöf O, Thonell S. Conventional abdominal radiography as a means to rule out ileo-caecal intussusception. *Acta Radiol Diagn* 1984; 25:265-267.
24. del-Pozo G, Albillos JC, Tejedor D. Intussusception: US findings with pathologic correlation - the crescent-in-doughnut sign. *Radiology* 1996; 199:688-692.
25. del-Pozo G, Albillos JC, Tejedor D, Calero R, Rasero M, de la Calle U, Lopez-Pacheco U. Intussusception in children: current concepts in diagnosis and enema reduction. *Radiographics* 1999; 19:299-319.
26. Bisset GS III, Kirks DR. Intussusception in infants and children: diagnosis and therapy. *Radiology* 1988; 168:141-145.
27. Verschelden P, Filiatraut D, Garel L, Grignon A, Perreault G, Boisvert J, Dubois J. Intussusception in children: reliability of US in diagnosis - a prospective study. *Radiology* 1992; 184:741-744.
28. Daneman A, Navarro O. Intussusception. Part 1: A review of diagnostic approaches. *Pediatric Radiology* 2003; 33(2):79-85.
29. Koumanidou C, Vakaki M, Pitsoulakis G, Kakavakis K, Mirilas P. Sonographic detection of lymph nodes in the intussusception of infants and young children: clinical evaluation and hydrostatic reduction. *Am J Roentgenol* 2002; 178:445-450.
30. Shanbhogue RL, Hussain SM, Meradji M, Robben SG, Vernooij JE, Molenaar JC. Ultrasonography is accurate enough for the diagnosis of intussusception. *J Pediatr Surg* 1994; 29:324-328.
31. Pracos JP, Tran-Minh VA, Morin de Finfe CH, Deffrenne-Pracos P, Louis D, Basset T. Acute intestinal intussusception in children: contribution of ultrasonography (145 cases). *Ann Radiol* 1987; 30:525-530.
32. Navarro O, Dugougeat F, Kornecki A, Shuckett B, Alton DJ, Daneman A. The impact of imaging in the management of intussusception owing to pathologic lead points in children. A review of 43 cases. *Pediatr Radiol* 2000; 30:594-603.
33. Sivit CJ, Siegel MJ. Gastrointestinal tract. *Pediatric Sonography* 2002; 3:337-383.
34. McAlister WH. Intussusception: even Hippocrates did not standardize his technique of enema reduction. *Radiology* 1998; 206:595-598.
-

35. Daneman A, Alton DJ. Intussusception: issues and controversies related to diagnosis and reduction. *Radiol Clin North Am* 1996; 34:743-756.

36. Schmit P, Rohrschneider WK, Christmann D. Intestinal intussusception survey about diagnostic and nonsurgical therapeutic procedures. *Pediatr Radiol* 1999; 29:752-761.

37. Riebel TW, Nasir R, Weber K. US-guided hydrostatic reduction of intussusception in children. *Radiology* 1993; 188:513-516.

38. Rohrschneider WK, Troger J. Hydrostatic reduction of intussusception under US guidance. *Pediatr Radiol* 1995; 25:530-534.

39. Rubi I, Vera R, Rubi SC, Torres EE, Luna A, Arcos J, et al. Air reduction of intussusception. *Eur J Pediatr Surg* 2002; 12:387-390.

40. Kirks DR. Diagnosis and treatment of pediatric intussusception: how far should we push our radiologic techniques? *Radiology* 1994; 191:622-623.

41. Woo SK, Kim JS, Suh SJ, Paik TW, Choi SO. Childhood intussusception: US-guided hydrostatic reduction. *Radiology* 182:77-80

42. Lund DP, Folkman J. Appendicitis. In: Walker WA, Durie PR, Hamilton JR, Walker-Smith JA, Watkins JB, eds. *Pediatric gastrointestinal disease: pathophysiology, diagnosis and management*. 2nd ed. St Louis, Mo: Mosby, 1996; 907-915.

43. Brenner D, Elliston C, Hall E, Berdon W. Estimated risks of radiation-induced fatal cancer from pediatric CT. *Am J Roentgenol* 2001; 176:289–296.

44. Taylor GA. Suspected appendicitis in children: In search of the single best diagnostic test. *Radiology* 2004; 231:293-295.

45. Garcia Pena BM, Mandl KD, Kraus SJ, Fischer AC, Fleisher GR, Lund DP, Taylor GA. Ultrasonography and limited computed tomography in the diagnosis and management of appendicitis in children. *JAMA* 1999; 282:1041-1046.

Competing Interests: None declared.

Funding: None.

This manuscript has been peer reviewed

Correspondence:

Robert A. Belfer, MD
16 Isaac Lane
Cherry Hill, NJ 08002
Cell: 609-472-0070
Fax: 856-667-1033
bobbelfer@msn.com