

Fractures Complicating Anterior Shoulder Dislocations in Adults

Wong JCT BSc¹, Thirsk WS MD¹ and Steiner IP MD^{2,3}

¹ Faculty of Medicine, University of Alberta, Edmonton AB, Canada

² Department of Emergency Medicine, University of Alberta, Edmonton AB, Canada

³ Department of Family Medicine, University of Alberta, Edmonton AB, Canada

Abstract

Anterior shoulder dislocations are the most common traumatic joint dislocation seen in Emergency Departments. Nevertheless, clinical data on the complications of anterior shoulder dislocations remain sparse. We describe a patient with 2 bony complications of an anterior shoulder dislocation and discuss the literature on the 3 most common types of complicating fractures that occur in this setting: Hill-Sachs lesion, Bankart fracture, and avulsion fracture of the greater tuberosity. This work is intended to alert emergency physicians to the importance of different axillary imaging techniques and anteroposterior views in internal or external rotation that may be necessary for the diagnosis of fractures accompanying anterior shoulder dislocations; to guide their assessment of the risk of recurrence or mobility restriction; and to help them prioritize consultations and referrals for best patient outcome.

MeSH Words: Anterior shoulder dislocation, emergency medicine, complications, fracture

Introduction

The annual incidence of shoulder injuries in North American urban settings is 2.19 per 1000 population, with a 1.7% prevalence of shoulder dislocations [1]. Sixty percent of all traumatic joint dislocations seen in the Emergency Departments (ED) involve the shoulder and 95% of these are displaced anteriorly. [1-3]. Posterior dislocations occur in about 5% of cases, and inferior shoulder dislocations (luxatio erecta) are extremely rare [4].

In anterior shoulder dislocations (ASDs), the humeral head is displaced anteriorly, to lie beneath the coracoid process in 70% of patients or inferior to the glenoid fossa in most of the

remainder [3]. Subclavicular and intrathoracic displacements are uncommon and are associated with violent forces and other fractures [5]. Because of the relatively frequent occurrence of ASDs, emergency physicians are usually well versed in the appropriate diagnostic and reduction techniques. However, clinical information on complications that may accompany ASDs remains sparse. Our review of the emergency medicine literature yielded only 4 relevant publications [4-7], none of which provided practical guidance in the identification and management of bony complications of ASDs in the emergency setting.

In the present report, we describe a patient who presented with a recurrent ASD and 2 distinct

bony fractures, and we review the literature on the 3 most frequently described fractures associated with ASDs. This work is intended to alert emergency physicians to the potential bony consequences of ASDs and to call attention to the available diagnostic imaging techniques. It will also help guide clinicians in prioritizing consultations and referrals for best patient outcome.

Case Presentation

A 43-year-old man presented to the ED with inability to move his severely painful right shoulder, precipitated by rolling over in bed. He stated on admission: "My shoulder is out again."

Past medical history revealed that the man had been treated in the ED 7 days previously for right traumatic ASD caused by a fall from a bicycle. Prereduction imaging study showed the dislocation (Figure 1); findings on the postreduction views were interpreted as normal. Treatment consisted of analgesic medication and immobilization of the shoulder in adduction and internal rotation. The chart does not mention any residual deficits or complications from the dislocation or reduction. He was followed 5 days later by an orthopedic surgeon who prescribed conservative management with progressive physiotherapy.

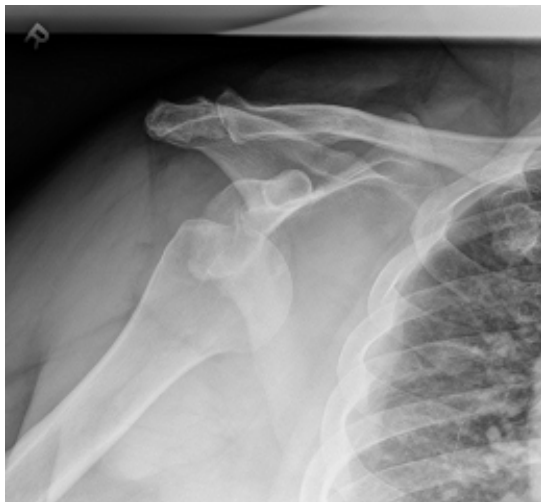

Figure 1: Prereduction anteroposterior view of the dislocated right shoulder.

Physical examination at the present ED admission revealed an obese middle-aged man in apparently severe pain, with normal vital signs. The right shoulder had a "squared off"

deformity: the arm was held in abduction, and the humeral head was palpated medial and inferior to the glenoid fossa. Loss of active and passive ranges of motion was noted. There were no neurovascular deficits.

Treatment consisted of closed reduction of the shoulder with the in-line traction technique under procedural sedation. The dislocation was reduced almost effortlessly. Assessment of range of motion under sedation demonstrated significant anterior and inferior instability proven by the easy dislocation and relocation of the humeral head. Postreduction imaging (Figure 2) showed anatomical reduction, a Hill-Sachs deformity of the humeral head, and a Bankart fracture of the glenoid. Comparison with the postreduction views from the first visit suggested that the bony Bankart injury had likely been present at that time. Computed tomography (CT) of the shoulder, performed after consultation with the radiologist, confirmed a large Hill-Sachs lesion and a Bankart fracture of the anterior-inferior rim of the glenoid cavity (Figure 3). We therefore consulted with the orthopedic surgeon on call, and the patient was discharged with a referral for urgent follow-up. Information on his further management and outcome was unavailable.

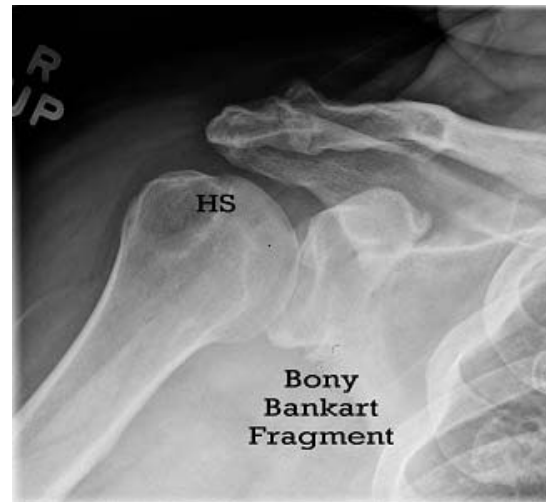


Figure 2: Postreduction anteroposterior view of the right shoulder (HS = Hill-Sachs lesion)

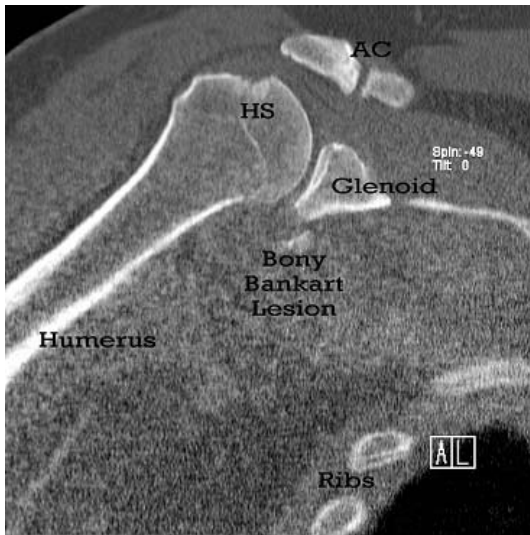


Figure 3: Reconstructed CT of the right shoulder – axillary view (HS = Hill-Sachs lesion)

Discussion

ASD accounts for 57% of all traumatic joint dislocations. Associated complications (Table 1) are common [4-7]. The 3 most frequently reported are Hill-Sachs lesion, bony Bankart fracture, and avulsion of the greater tuberosity of the humerus.

Hill-Sachs Lesion

Hill-Sachs lesions are wedge-shaped compression fractures of the posterolateral humeral head [8]. They are more common in people younger than 40 years, probably because of the stronger rotator cuff in this age group, which adds to the forces pushing the humeral head against the glenoid [4]. For diagnosis with plain imaging, an orthogonal or axillary view in 0-15° gently assisted abduction is best [9]. However, when the patient is in pain, which often prevents even a small degree of abduction, a modified axillary view without movement of the arm is recommended [10]. Anteroposterior (AP) view with the arm in internal rotation may show a lucency on the lateral aspect of the humeral head, parallel to the shaft's axis. Other plain image views are noncontributory [2,9]. CT and magnetic resonance imaging (MRI) are more sensitive than plain radiographs, but their use in ED management is limited [11].

Although Hill-Sachs lesions are often dismissed as “benign” or clinically unimportant, there is

evidence that when they are visible on plain x-ray films, they predict a greater likelihood of recurrent dislocations [12]. Others have reported an association of Hill-Sachs lesions with a greater number of recurrent ASDs, and an association of recurrent ASDs with greater size of Hill-Sachs lesions [5,13,14]. Using MRI, physicians detected Hill-Sachs fractures in 67% of patients with primary traumatic ASDs and 70% of patients with recurrent ASDs, suggesting that they were almost always present already at the first episode [8].

Although the timing of the operative management of Hill-Sachs fractures associated with primary or recurrent dislocations is not clear, a recent publication recommended early surgical intervention to prevent recurrence of ASD [14].

Bankart Fracture

Bankart lesions are characterized by damage to the glenohumeral ligament and anteroinferior cartilaginous labrum when the humeral head is forced out of the joint space. If the bony margin of the glenoid is involved, it is called a “bony Bankart lesion” or “Bankart fracture” [4,15]. The mechanism of injury is similar to that in Hill-Sachs lesions, and like Hill-Sachs lesions, Bankart fractures are more prevalent in younger people. [4]. They reportedly complicate 0 to 20% of all cases of ASD [6,15].

On plain AP view, opacities below the glenoid rim should raise a suspicion of bony Bankart lesion. The diagnosis can be confirmed by West Point axillary view, CT or MRI [8,11,16]. MRI is superior for the diagnosis of cartilage and capsulolabral injuries [8,11].

Bankart fractures contribute to anterior shoulder instability and recurrent dislocations [4]. The larger the bone defect, the more significant the joint instability and the greater the likelihood of recurrent ASD [15,17]. Bankart fractures often occur in conjunction with Hill-Sachs lesions, and if one is identified, the other is 2.67 times more likely to be present [8]. Bankart fractures, similar to Hill Sachs injuries, have been detected at equal rates in patients with primary (73%) and recurrent (72%) ASD, suggesting that they most likely occur with the initial shoulder dislocation. Unrecognized Bankart fractures are associated

with recurrent ASD in patients with “failed” surgical repair [18].

Avulsion of Greater Tuberosity

During ASD, if the humerus rotates and the greater tuberosity impacts against the glenoid rim as it moves toward the acromion, the rotator cuff muscles may be torn away from their attachments or the greater tuberosity may fracture [5,6,19]. This injury happens in 10-15 % of ASDs. Although more common in female patients aged over 40 years, it may also be seen in younger male patients with high-energy injuries (Table 1) [2,19]. The fracture and degree of displacement are best detected on plain AP view with the arm in external rotation. If pain precludes this, an AP view with internal

rotation and 15° cephalic tilt should be used. Axillary views are helpful, but other plain image views are not contributory. Like for the other complications, CT and MRI, when available, are better diagnostic tools than plain x-ray [8,19].

Recurrent dislocations are uncommon in patients with avulsion fractures of the greater tuberosity unless they are associated with high-energy injuries and bony Bankart lesions [20,21].

Displaced greater tuberosity fractures may cause a mechanical block of shoulder abduction or subacromial impingement. Even in the absence of a mechanical block, altered functioning of the rotator cuff tendons may lead to restricted shoulder abduction and strength. There is no consensus on the timing of surgical repair of avulsion of the greater tuberosity [19].

Table 1: Complications of anterior shoulder dislocations

Category and Type	Frequency	Patient Age Group (yr)
Recurrence	>65%	<20
	41%	20-40
	10%	> 40
Fractures	Overall: 30%	
Hill-Sachs lesion	54-76%*	<40
Bony Bankart lesion	0-20%*	<40
Avulsion of greater tuberosity	10-16%*	?>40
Coracoid process lesion	Rare*	>40
Humeral shaft lesion	Rare*	All
Glenohumeral ligaments	55-80%	<40
Rotator cuff	35-86%	>40
Neurological injury	Overall: 21-50%	>40
Axillary nerve	42%	>40
Radial nerve	7%	>40
Brachial plexus	Rare	>40
Vascular injury		
Axillary artery injury	Rare, but 86%in	>50
Subclavian vein thrombosis	Rare	Not listed

* % of all fractures associated with ASD.

Review of the Case

In the present patient with recurrent ASD, axillary views were not obtained at the initial ED presentation because our department routinely uses AP and transcapular views to verify the relocation of ASDs. Axillary or modified axillary views would have identified the Bankart fracture. At the second visit, both the Hill-Sachs and bony Bankart lesions were visualized on

plain images, and a CT scan of the shoulder was performed instead of the axillary view.

The omission of prerotation imaging on the return visit was consistent with the Banff Shoulder Dislocation Guidelines which state that x-rays need not be performed before reduction by experienced emergency physicians who are clinically certain of ASD [22]. These authors also claimed that appropriate reduction does not

worsen the underlying fractures. However, others urge caution in foregoing prerotation views because some patients may be at high risk of fractures that might displace or need surgical treatment [23]. Preliminary data suggest that prerotation x-ray examination may be useful in the presence of the following criteria: first ASD, patient age more than 40 years, or injury due to a fall of more than one flight of stairs, assault, or high-speed motor vehicle collision. In our case, although we believe that the Hill-Sachs lesion was not attributable to the easy reduction, we were unable to verify when and how it happened.

Systematic review studies of the definitive interventional and conservative management strategies for traumatic ASD have yielded inconclusive findings [24,25]. There is limited support for primary surgery, even in the absence of complicating fractures, in young adult males involved in highly demanding physical activities [24]. The best type of immobilization (e.g., internal rotation and adduction or external rotation and abduction) and the appropriate duration of immobilization are unknown [25], although there is some preliminary evidence suggesting that immobilization in external rotation and abduction is beneficial [25,26].

In our case, urgent consultation with an orthopedic surgeon after the first visit was not warranted given the patient's age (43 years), obesity, and the diagnosis of "uncomplicated ASD." It was, however, appropriate at the second admission because of the recurrent dislocation, significant joint instability, and finding of 2 additional fractures which further contributed to the instability.

The ED immobilization of the shoulder in adduction was in keeping with current treatment practice.

Recommendations

The radiological diagnosis of ASD is enhanced by use of plain AP views in external or internal rotation. Simple, modified, or West Point axillary images are extremely helpful. CT and MRI are more sensitive, but their use in further diagnosing these fractures in the ED is usually undertaken in consultation with an orthopedic surgeon or radiologist.

Immediate consultation with an orthopedic surgeon is required for patients with an unsuccessful ED reduction and patients with neurovascular injuries or open fractures.

Consultation is also recommended for patients with a bony Bankart lesion, alone or in combination with a Hill-Sachs lesion, or a displaced avulsion fracture of the greater tuberosity, in order to expedite the detailed anatomical diagnosis by CT or MRI and to decide on definitive treatment.

Patients discharged from the ED require adequate analgesia, immobilization as dictated by local practice, and prioritized follow-up arrangements.

Young adults of both genders who are involved in highly demanding physical activities, even in the absence of complicating fractures, may benefit from primary repair and should be given an urgent referral (within 14 days) to an orthopedic surgeon. This is also true for patients with primary traumatic ASD and a visible Hill-Sachs lesion on plain x-ray films who are younger than 40 years or older than 40 years but very active.

Patients with recurrent ASD and identified Hill-Sachs deformities may be referred to an orthopedic surgeon on a non-urgent basis.

All others should be followed by the primary care provider.

Conclusions

Routine plain view radiography for ASD in the ED often does not include various axillary imaging techniques or AP views in internal or external rotation, which may be essential for diagnosing Hill-Sachs lesions, Bankart fracture, and avulsion fractures of the greater tuberosity. When in doubt, emergency physicians must insure that these views are used.

Decisions regarding surgical consultation or referral should be based on the likelihood that operative intervention will be needed to urgently restore the functional anatomy or to prevent high-risk recurrences or severe restriction of mobility. Clear indications include dislocations that are irreducible in the ED, open fractures, and neurovascular injuries. The management of the

remaining patients should be based on our recommendations, with consideration of the patient's age, level and type of physical activities the patient is engaged in, and the nature and number of fractures.

References

1. Emond M, Lesage N, Lavoie A, Rochette L. Clinical factors predicting fractures associated with an anterior shoulder dislocation. *Acad Emerg Med* 2004; 11:853-858.
2. Ceroni D, Sadri H, Leuenberger A. Radiographic evaluation of anterior dislocation of the shoulder. *Acta Radiol* 2000; 41:658-61.
3. DePalma AF, Flannery GF. Acute anterior dislocations of the shoulder. *Am J Sports Med* 1973; 1:6-15.
4. Beeson MS. Complications of shoulder dislocations. *Am J Emerg Med* 1999; 17:288-295.
5. Cunningham NJ. Techniques for reduction of anteroinferior shoulder dislocations. *Emerg Med Australas* 2005; 17:463-471.
6. Perron AD, Ingerski MS, Brady WJ, Erling BF, Ullman EA. Acute complications associated with shoulder dislocations at an academic emergency department. *J Emerg Med* 2003; 24:141-145.
7. Ameh V, Crane S. Nerve injury following shoulder dislocation: the emergency physician's perspective. *Eur J Emerg Med* 2006; 13:233-235.
8. Widjaja A, Tran A, Bailey M, Proper S. Correlation between Bankart and Hill-Sachs lesions in anterior shoulder dislocations. *ANZ J Surg* 2006; 76:436-438.
9. Harris JH. Emergency radiology primer. http://www.uth.tmc.edu/radiology/test/er_primer/shoulder/shoulder.html Accessed August 20,2007.
10. Geusens E, Pans S, Verlhust D, Brys P. The modified axillary view of the shoulder, painless alternative. *Emerg Radiol* 2006; 12:227-230.
11. Kirkley A, Litchfield R, Thain L, Spouge A. Agreement between magnetic resonance imaging and arthroscopic evaluation of the shoulder joint in primary anterior dislocations of the shoulder. *Clin J Sports Med* 2003; 13:148-151.
12. Hovelius L, Augustini BG, Fredin H, Johansson O, Norlin R, Thorling J. Primary anterior shoulder dislocation of the shoulder in young patients. A ten-year prospective study. *J Bone Joint Surg Am* 1996; 78:1677-1684.
13. Spatschil A, Landsiedl F, Anderl W, Imhoff A, Seiler H, Vassilev I, et al. Posttraumatic anterior-inferior instability of the shoulder: arthroscopic findings and clinical correlations. *Arch Orthop Trauma Surg* 2006; 126:217-222.
14. Cetik O, Uslu M, Ozsar BK. The relationship between Hill-Sachs lesion and recurrent anterior shoulder dislocation. *Acta Orthop Belg.* 2007; 73:175-178.
15. Takase K, Yamamoto K. Intraarticular lesions in traumatic anterior shoulder instability; a study based on the results of diagnostic imaging. *Acta Ortho* 2005; 76:854-857.
16. Itoi E, Seok-Beom L, Amrami KK, Wenger DE, Kai-Nan A. Quantitative assessment of classic anteroinferior bony Bankart lesions by radiography and computed tomography. *Am J Sports Med* 2003; 31:112-118
17. Itoi E, Seok-Beom L, Berglund LJ, Berge LL, Kai-Nan A. The effect of a glenoid defect on anteroinferior stability of the shoulder after Bankart repair: a cadaveric study. *J Bone Joint Surg Am* 2000; 82:35-46.
18. Meehan RE, Petersen SA. Results and factors affecting outcome of revision surgery for shoulder instability. *J Shoulder Elbow Surg* 2005; 14:31-37.
19. Dimankopoulos P, Panagopoulos A, Kasimatis G, Syggelos SA, Lambris E. Anterior traumatic shoulder dislocation associated with displaced greater tuberosity fragment: the necessity for operative treatment. *J Orthop Trauma* 2007; 21:104-112.
20. Rowe CR. Acute and recurrent anterior dislocations of the shoulder. *Orthop Clin North Am* 1980; 11:253-270.

21. Kralinger FS, Golser K, Wischatta R, Wambacher M, Sperner G. Predicting recurrence after primary anterior shoulder dislocation. *Am J Sports Med* 2002; 30:116-120.
22. Schuster M, Abu-Laban R, Boyd J, Gauthier C, Shepherd L, Turner C. Prospective evaluation of a guideline for the selective elimination of pre-reduction radiographs in clinically obvious anterior shoulder dislocations. *CJEM* 2002; 4:257-262.
23. Emond M, LeSage N, Lavoie A, Rochette L. Clinical factors predicting fractures associated with an anterior shoulder dislocation. *Acad Emerg Med* 2004; 11:853-858.
24. Handoll HHG, Almayyah MA. Surgical versus non-surgical treatment of acute anterior shoulder dissociations. *Cochrane Database of Systematic reviews*. 2007; 3.
25. Handoll HHG, Hanchard NCA, Goodchild L, Feary J. Conservative management following closed reduction of traumatic anterior dislocations of the shoulder. *Cochrane Database of Systematic reviews*. 2007; 3.
26. Itoi E, Sashi R, Minagawa H, Shimizu T, Wakabayashi I, Sato K. A new method of immobilization after traumatic anterior dislocation of the shoulder: preliminary study. Presented at the meeting of the American Academy of Orthopaedic Surgeons; February 5-9, 2003; New Orleans, LA.

Contribution of Authors: All three authors reviewed the literature independently and contributed to writing the manuscript. Mr. Wong (medical student) generated the idea for the manuscript. Dr. Thirsk (clinical lecturer) provided input as an expert in sports medicine and retrieved the diagnostic images. Dr. Steiner (professor) provided the case.

Competing Interests: None declared.

Funding: None declared.

This manuscript has been peer reviewed.

Correspondence:

Ivan P Steiner BSc, CScM MD
Faculty of Medicine
University of Alberta
Tel: (780) 492-0582
Fax: (780) 492-8191

e-mail: ivan.steiner@ualberta.ca