

A Rare Cause of Acute Dyspnea in the Emergency Department: Pulmonary Cement Embolism

Wermuth J MD¹, Meckel S MD², Wetzel FT MD² and Bingisser R MD¹

¹*Emergency Department, University Hospital Basel, Basel, Switzerland*

²*Department of Radiology, University Hospital Basel, Basel, Switzerland*

Abstract

We describe an elderly man who presented to the Emergency Department with dyspnoea induced by a pulmonary cement embolism following vertebroplasty. The diagnosis was made by chest x-ray. Treatment consisted of anticoagulation with heparin. The dyspnea resolved after 7 days, with no sequelae.

Vertebroplasty, used for the treatment of osteoporotic fractures in addition to hemangiomas and malignant tumors, may in rare cases be complicated by symptomatic, occasionally life-threatening, cement leakage into the paravertebral venous plexus. It is important that clinicians be alerted to this new emergency medical entity because, owing to the radio-opacity of the cement, it can be diagnosed rapidly on x-ray film if the physician knows what to look for. Though the value of preventive anticoagulation therapy is not proven in this setting, we recommend its use for 6 months, until the embolized material is endothelialized.

MeSH Words: Emergency, dyspnea, bone cement, pulmonary embolism

Introduction

Vertebroplasty is a minimally invasive technique wherein acryl and/or calcium phosphate bone cement is injected transpedicularly into a vertebral body. It is being increasingly used to treat osteoporotic vertebral fractures, but it is also applied for infiltrations of malignant tumors as well as for hemangiomas. In up to 70% of vertebroplasty interventions, cement escapes from the vertebral body. Though this complication is usually asymptomatic, entry of the cement into the intervertebral area, neuroforamina, or epidural space can have immediate and serious consequences (nerve compression, cauda equina syndrome) and lead to long-term morbidity (spinal stenosis with

myopathy, chronic pain). All of these may involve visits to the Emergency Department. In rare cases, cement may leak into the paravertebral venous plexus, leading to pulmonary embolism. Because bone cement shows mineral density on x-ray film, emboli in the main and segmental pulmonary arteries can be rapidly diagnosed, provided that the clinician is aware of the syndrome and actively looks for it.

We describe an elderly man who presented to the Emergency Department with dyspnea induced by a pulmonary cement embolism following vertebroplasty.

Case Report

An 80-year-old man (86 kg, 170 cm) was admitted to the Emergency Department because of steadily worsening dyspnea which had begun one day after vertebroplasty. He had no complaints of chest pain or any other signs or symptoms, such as cough, oedema, or weight gain. The dyspnea was graded NYHA class III.

Past history revealed insulin-dependent diabetes mellitus and hypertension of many years' duration. Two years before the present admission, the patient was diagnosed with temporal arteritis, and therapy with 30 mg prednisone was started. By the time of admission, there had been no change in the daily dose.

One year later, with the patient under steroid therapy, osteodensitometry revealed severely low density of the femoral bone and osteopenic structure of the lumbar spine. Treatment with calcium and vitamin D supplements and bisphosphonate as well as parathyroid hormone yielded no clinical benefit. Magnetic resonance imaging (MRI) of the spine demonstrated a fracture with signs of oedema (contrast enhancement on T1-weighted sequences) at vertebral bodies L1 through L4. When the lumbar pain proved resistant to nonsteroidal antirheumatic agents for one year, vertebroplasty of L3/4 was performed. No neurological symptoms were ever noted.

The intervention was performed under general anaesthesia. The position of the L3 and L4 vertebrae was verified by conventional x-ray examination, and they were punctured transpedicularly with 10G needles. However, shortly after the start of calcium phosphate cement injection, extravasation of the material into a paravertebral vein was documented. The injection was immediately stopped. A second puncture was made contra laterally, and the vertebroplasty was completed using acrylic cement. The following day, the patient reported considerably less lumbar pain, and he was discharged. The dyspnea started the same day, on his return home, and increased thereafter. That night, he presented to our Emergency Department.

Clinical examination at admission showed no pathological signs. Blood pressure measured

145/80 mmHg, pulse 70 beats/min. Arterial blood gas analysis yielded almost normal values: partial arterial oxygen tension (PaO₂) 10.6 kPa and partial pressure of carbon dioxide (PaCO₂) 4.5 kPa. Findings on blood chemistry analysis, including levels of C-reactive protein, troponin, myoglobin, and brain natriuretic peptide, were within normal range. The electrocardiogram showed sinus rhythm with no signs of right heart failure or strain and normal repolarization. X-ray films of the lumbar spine revealed cement leakage into the anterior venous plexus (Fig. 1). Emergency chest x-ray showed a structure of mineral density in the area of the left pulmonary artery, suggesting cement embolism (Fig.2).

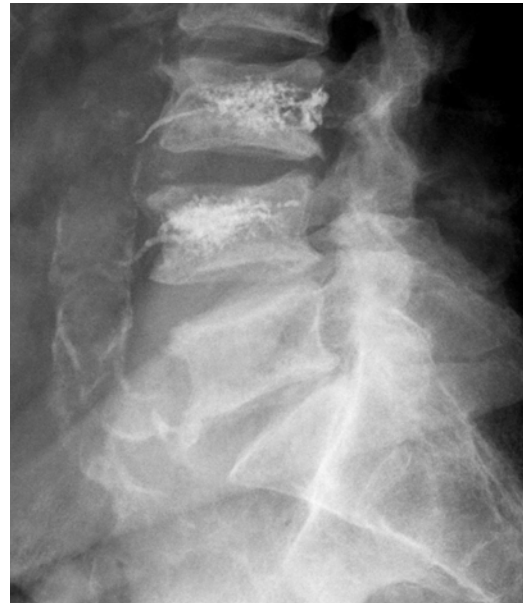

Figure 1: X-ray film of the lumbar spine showing cement leakage after vertebroplasty.

After diagnosis, immediate anticoagulation with heparin was started. Three days later, multislice spiral computed tomography of the chest showed a foreign body within the left pulmonary artery (Fig.3). The dyspnea resolved over 7 days and the patient was discharged home. At that time, he reported a considerable improvement in lumbar pain from before the intervention. On follow-up at 3 months after discharge, the patient appeared in good health, with little lumbar pain and no dyspnea.

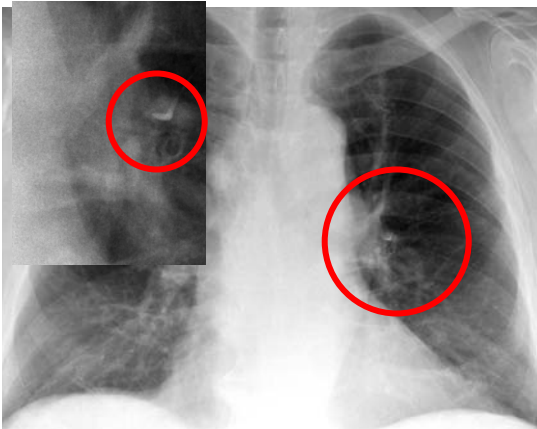


Figure 2: Chest x-ray film showing radio-opaque emboli in the left main pulmonary artery (enlarged view: left upper quadrant).

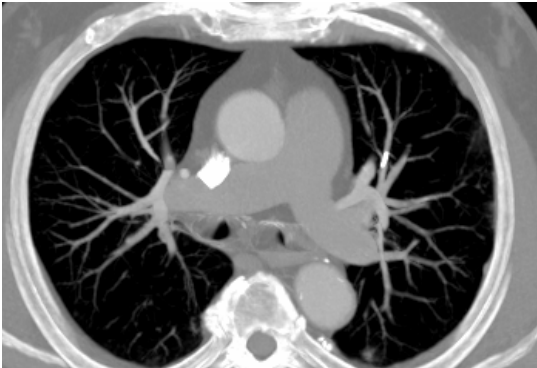

Figure 3: CT scan showing the solitary cement-embolus in the left pulmonary artery.

Discussion

Bone cement was developed for orthopaedic joint replacement surgery. Both calcium phosphate and acrylic bone cement are currently being used. Minimally invasive vertebroplasty was introduced in 1987 for the treatment of hemangiomas [1] and is being increasingly applied for metastases and for osteoporotic fractures [2-4] with refractory pain [5], as in our patient. Bone scan imaging showing vertebral oedema may be considered indicative of micro-instability and appears to have equal value to conventional scintigraphy [3,6] as a predictor of successful intervention. During vertebroplasty, the vertebral bodies are punctured percutaneously and transpedicularly with a 10-13 gauge biopsy needle, unilaterally or bilaterally. The trocar is then removed and bone cement is injected through the needle.

A clinical response may be achieved within days [2,8]. Several retrospective studies reported a

promising effect of vertebroplasty on limb mobility and reduction of pain medication [4,5,7]. Amar et al. [2] observed a significant improvement in quality of life in 75- 80% of patients with refractory lumbar pain from vertebral fractures.

The exact mechanism underlying the effect of vertebroplasty remains unclear. Suggestions include stabilization of the vertebral body, prevention of further microfractures, as well as heat-induced impact on nerve structures or toxic effects [2,5].

Vertebroplasty is not free of complications. During injection, the cement can leak out of the vertebral bodies into the inter- or paravertebral space: for tumor infiltrations, the estimated rate is 38-72 %; for osteoporotic fractures, 30-65% [9]. Although most cases seem to be asymptomatic [2,10], systemic complications have not been methodically assessed [5]. Neuroforaminal involvement can lead to radicular symptoms and require surgical decompression [10]. Systemic complications are also possible with cement leakage into the ventral venous plexus. Furthermore, the rapid hardening of the bone cement poses a risk of pulmonary embolism. Although Layton et al. [11], in a study of 1000 vertebral fractures treated with vertebroplasty, noted symptomatic pulmonary embolism in only one patient, Three earlier studies that employed post interventional chest x-ray screening reported pulmonary embolism rates from 4.6- 5% [2,12] to 11% [13]. Most of the affected patients were asymptomatic [12]. In the remainder, symptoms were typical of pulmonary embolism of other etiologies: dyspnea, cough, chest pain, hypotension, and acute right heart failure [14,15].

The indications for anticoagulation in this setting have not been studied. Most patients with asymptomatic cement embolism reported in the literature remained untreated [12]; in symptomatic patients, however, anticoagulation was started immediately. Emergency pulmonary embolectomy was performed in patients with cardiogenic shock [14,16]. In addition, to prevent further appositional thrombus formation, anticoagulation with heparin, low-molecular heparin, or warfarin has been used. However, this practice is questionable [4] because it is still unknown if appositional thrombus formation

indeed occurs regularly around pulmonary cement embolisms. According to in vitro studies, acrylic cement does not lead to plasma coagulation or platelet aggregation [17]. Remarkably, in a case study of severe pulmonary cement embolism with right heart failure, clinical improvement was not achieved with heparin therapy for 48 hours; embolectomy, performed thereafter, led to a rapid recovery [16]. In another patient with multiple pulmonary cement embolisms, mechanical ventilation for 10 days without anticoagulation ultimately led to clinical improvement [18]. In our patient, the striking history combined with the steadily increasing dyspnea over several hours may have been indicative of appositional thrombus formation [19].

The duration of anticoagulation is also unclear. We decided that 6 months of therapy was adequate for our patient because endothelialization of the thrombus can be expected after this time [19].

Conclusion

Pulmonary cement embolism after vertebroplasty is a new entity to which emergency medicine physicians should be alerted. Although acute dyspnea is rarely associated with a pulmonary embolism from a foreign body, this possibility should not be overlooked in the setting of vertebroplasty. Other symptoms of cement embolism include chest pain and even right heart failure. In suspect cases, physicians should critically review the conventional chest x-ray films for radio-opaque bodies within the pulmonary vascular tree. In cases of cardiogenic shock, rapid surgical thrombectomy should be considered, since there is no documented benefit of thrombolytic therapy. We suggest that because bone cement might trigger a local thrombosis, anticoagulation in symptomatic patients, though not of scientifically proven value, may be helpful. Six months' treatment should be sufficient, since after this time, the embolized material should be endothelialized and the risk of further thrombosis is minimal.

References

1. Galibert P, Deramond H, Rosat P, Le Gars D. Preliminary note on the treatment of vertebral

angioma by percutaneous acrylic vertebroplasty. *Neurochirurgie* 1987; 33(2):166-168.

2. Amar AP, Larsen DW, Esnaashari N, Albuquerque FC, Lavine SD, Teitelbaum GP. Percutaneous transpedicular polymethylmethacrylate vertebroplasty for the treatment of spinal compression fractures. *Neurosurgery* 2001; 49(5):1105-1114.

3. Burton AW, Rhines LD, Mendel E. Vertebroplasty and kyphoplasty: a comprehensive review. *Neurosurg Focus* 2005; 18:1-9.

4. Levine SA, Perin LA, Hayes D, Hayes WS. An evidence-based evaluation of percutaneous vertebroplasty. *Managed Care* 2000; 9(3):56-60.

5. Evans AJ, Jensen ME, Kip KE, DeNardo AJ, Lawler GJ, Negin GA, et al. Vertebral compression fractures: pain reduction and improvement in functional mobility after percutaneous polymethylmethacrylate vertebroplasty retrospective report of 245 cases. *Radiology* 2003; 226(2):366-372.

6. Maynard AS, Jensen ME, Schweickert PA, Marx WF, Short JG, Kallmes DF. Value of bone scan imaging in predicting pain relief from percutaneous vertebroplasty in osteoporotic vertebral fractures. *Am J Neuroradiol* 2000; 21(10):1807-1812.

7. Gangi A, Guth S, Imbert JP, Marin H, Dietemann JL. Percutaneous vertebroplasty: indications, technique, and results. *Radiographics* 2003; 23(2):e10.

8. Anselmetti GC, Corgnier A, Debernardi F, Regge D. Treatment of painful compression vertebral fractures with vertebroplasty: results and complications. *Radiol Med* 2005; 110(3):262-272.

9. Laredo JD, Hamze B. Complications of percutaneous vertebroplasty and their prevention. *Skeletal Radiol* 2004; (9):493-505.

10. Cotten A, Dewatre F, Cortet B, Assaker R, Leblond D, Duquesnoy B, et al. Percutaneous vertebroplasty for osteolytic metastases and myeloma: effects of the percentage of lesion filling and the leakage of methyl methacrylate at

clinical follow-up. *Radiology* 1996; 200(2):525-530.

11. Layton K, Thielen K, Koch C, Luetmer P, Lan J, Wald J, Kallmes D. Vertebroplasty, first 1000 levels of a single center: evaluations of the outcomes and complications. *Am J Neuroradiol* 2007; 28(4):683-689.

12. Choe DH, Marom EM, Ahrar K, Truong MT, Madewell J. Pulmonary embolism of polymethyl methacrylate during percutaneous vertebroplasty and kyphoplasty. *Am J Roentgenol* 2004; 183(4):1097-1102.

13. Jang JS, Lee SH, Jung SK. Pulmonary embolism of polymethylmethacrylate after percutaneous vertebroplasty: a report of three cases. *Spine* 2002; 27(19):E416-E418.

14. François K, Taeymans Y, Poffyn B, Van Nooten G. Successful management of a large pulmonary cement embolus after percutaneous vertebroplasty: a case report. *Spine* 2003; 28(15):E424-425.

15. Stricker K, Orlor R, Yen K, Takala J, Luginbühl M. Severe hypercapnea due to pulmonary embolism of polymethylmethacrylate during vertebroplasty. *Anesth Analg* 2004; 98(4):1184-1186.

16. Tozzi P, Abdelmoumene Y, Corno AF, Gersbach PA, Hoogewoud HM, von Segesser LK. Management of pulmonary embolism during acrylic vertebroplasty. *Ann Thorac Surg* 2002; 74(5):1706-1708.

17. Blinc A, Bozic M, Vengust R, Stegnar M. Methyl-methacrylate bone cement surface does not promote platelet aggregation or plasma coagulation in vitro. *Thromb Res* 2004; 114(3):179-184.

18. Scroop R, Eskridge J, Britz GW. Paradoxical cerebral arterial embolization of cement during intraoperative vertebroplasty: case report. *Am J Neuroradiol* 2002; 23(5):868-870.

19. Righini M, Sekoranja L, Le Gal G, Favre I, Bounameaux H, Janssens JP. Pulmonary cement embolism after vertebroplasty. *Thromb Haemost* 2006; 95(2):388-389.

Contribution of Authors: No study group, no editorial authorship.

Competing Interests: None declared.

Funding: None declared.

This manuscript has been peer reviewed

Correspondence:

Prof. Roland Bingisser
Director
Emergency Department
University Hospital Basel
4031 Basel, Switzerland.
Tel: +41 61 265 58 30
Fax: +41 61 265 58 31

e-mail: BingisserR@uhbs.ch