

Morbidity and Mortality Rounds: A Case of Chest and Right Shoulder Pain

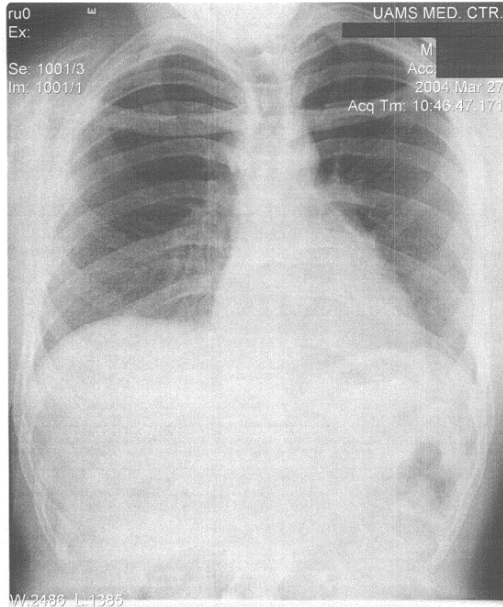
Abbie Collinsworth, MD; Lawrence L. Kass, MD; Rebecca L. Liggin, MD; Barry E. Brenner, MD

*Department of Emergency Medicine; University of Arkansas for Medical Sciences;
Arkansas, USA*

Dr. Collinsworth: I am presenting a twenty one year old male complaining of right shoulder and lower neck pain. The patient was wrestling last night with co-worker and the co-worker fell on him. The co-worker's shoulder impacted the patient on his right shoulder and clavicle. Immediately, he noted he was unable to move his shoulder, but denied numbness, tingling or shortness of breath. He took Tylenol during the night for pain, but presented to the emergency department the next morning because

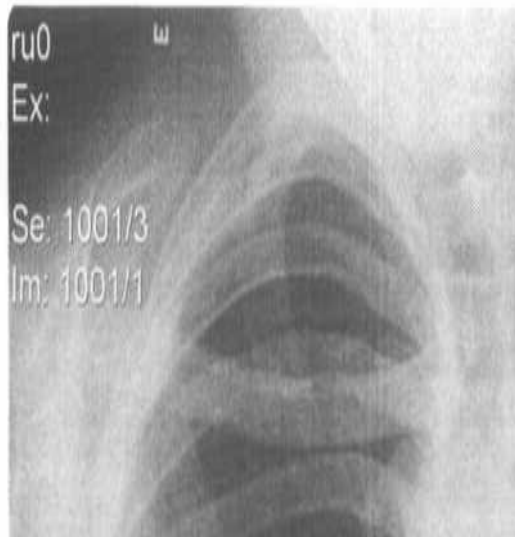of increasing pain, and now numbness in his right hand. His past medical history is negative, surgical history is negative. He denies previous injury to the shoulder. With the exception of pain and numbness his review of systems is otherwise negative. Specifically, he denies chest pain, shortness of breath and back pain.

Dr. Kass: What is in your differential at this point?



Dr. Collinsworth: On physical exam, his vital signs are: temperature 98.1, pulse 69, respiration 16, blood pressure 135/72. His oxygen saturation on room air was 97%. He is mildly anxious. His right shoulder is mildly tender to palpation anterior and posterior, more prominent over the acromioclavicular joint. The clavicle demonstrated increasing tenderness as the sternum was approached. There was edema noted over the right sternoclavicular joint. The patient had pain and limitation with active and passive range of motion, able only to abduct to 20 degrees and internally rotate to 5 degrees. The radial and ulnar pulses were 2+ and sensation in the ulnar, radial and median nerve distributions were intact to pinprick, temperature and 2 point discrimination. Motor exam was limited by pain. Cervical, thoracic and lumbar spine demonstrated full range of motion and were non-tender to palpation. The remainder of his physical exam was unremarkable -

Dr. Kass: What did you do next?



Dr. Collinsworth: An posteroanterior and lateral chest x-ray, and 3 view shoulder xrays were obtained, which were read as negative for fractures, dislocations. The patient was given 600 mg of Ibuprofen, which on repeat exam did not provide any pain relief, nor was he able to demonstrate any improvement in range of motion.

Dr. Kass: At this point, what is in your differential?

Dr. Collinsworth: acromioclavicular separation, occult clavicular fracture, sternoclavicular dislocation or separation, both anterior and posterior, pneumothorax, chest wall pain, musculoskeletal pain.

Dr. Collinsworth: Anterior, posterior or inferior shoulder dislocation, acromioclavicular separation, clavicular fracture, scapular fracture, anterior or posterior sternoclavicular subluxation or dislocation.

An emergency medicine resident: Was there a step off or other bony abnormality palpated at the SC joint?

Dr. Kass: What did you find on exam?

Dr. Collinsworth: No, there was a significant amount of soft tissue edema over the joint making palpation of the joint very difficult.

An emergency medicine resident: Can a sternoclavicular dislocation be seen on plain film?

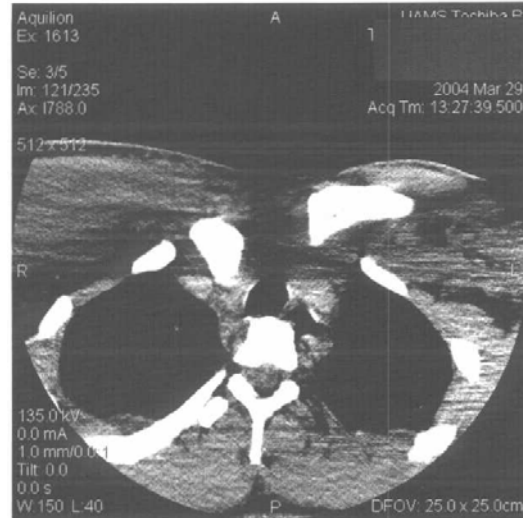Dr. Collinsworth: The traditional anteroposterior view is not useful, however, a serendipity view which is taken with 40 degrees of cephalic tilt can occasionally demonstrate the clavicle projecting either above the horizontal plane in anterior dislocations or below the plane in posterior dislocations. Additionally, the Hobb's view which is a 90 degree cephalocaudal lateral view of the SC joint may also demonstrate these dislocations.⁽¹⁾ These views were not done in this patient. The chest x-ray did seem to have a mild degree of inferior displacement but this was not definitive.

An emergency medicine resident: What is the definitive study for SC dislocation?

Dr. Collinsworth: CT scan with 3 mm axial images. This will demonstrate not only the musculoskeletal structures most effectively, it also allows for study of the underlying structures that can be at risk with a posterior SC dislocation.

Dr. Kass: Is there a grading system for dislocations?

Dr. Collinsworth: Yes. These are divided as follows: a 1st degree dislocation is known as a sprain which is a partial tear of sternoclavicular and costoclavicular ligament, a 2nd degree is a subluxation, which is a complete tear of the sternoclavicular ligament plus partial tear of the costoclavicular ligament, and the clavicle is subluxed from the manubrium, a 3rd degree which is known as a dislocation is a complete tear of both ligaments with dislocation of clavicle from manubrium, it may be either anteriorly or posteriorly dislocated.



Dr. Kass: What are the complications that you need to be concerned about with a posterior dislocation?

Dr. Collinsworth: Trauma to the great vessels, trachea, esophagus, and brachial plexus, which are immediately posterior to the SC joint, make this dislocation life-threatening. In a study by Ono et al, in 1998, of 102 cases identified with posterior SC dislocation approximately 30% had one of these complications.² In the case of this patient, the CT demonstrated posterior dislocation of the medial end of the left clavicle in relation to the sternoclavicular joint, with a buckled fracture of the medial third of the clavicle. The displaced end of the clavicle is impinging on the innominate artery at its bifurcation. There was no hematoma noted, however, contrast would be needed for further vessel evaluation.

An emergency medicine resident: How would you then manage this patient?

Dr. Collinsworth: Ideally, reduction of a posterior SC dislocation should occur in the operating room under general anesthesia once the underlying structures have been fully evaluated with contrast CT, specifically looking at the great vessels. It is recommended that a cardiothoracic surgeon be present in the operating room with the orthopedic surgeon. If

there is any evidence of airway or vascular compromise, emergent reduction may be required in the emergency department. The patient is positioned supine with a rolled towel between the shoulders. Traction is applied in an extended and abducted position. If this is unsuccessful, using sterile technique, prepare the skin overlying the clavicle and grasp it with a towel clip and pull out in an anterior and lateral fashion.

Dr. Collinsworth: Injuries to the SC joint are also graded to assist in management. A grade I injury is a mild strain with intact ligaments and treated with sling, ice, nonsteroidal anti-inflammatories; a grade II injury involves complete rupture of the SC ligament and partial rupture of the costoclavicular ligament. Treatment involves a figure of eight harness and referral to orthopedics for follow-up; and grade III which is dislocation with complete ligament disruption. Treatment consists of reduction, either open or closed, figure of eight harness and referred for orthopedic followup.

Dr. Kass: What was the outcome in this patient?

Dr. Collinsworth: A closed reduced was attempted but was unsuccessful. The patient was taken to the operating room where a successful open reduction was performed. Post-repair CT images demonstrated intact vasculature. The patient did well during his hospital course.

References:

- 1) Williams C. Posterior Sternoclavicular Joint Dislocation. *The Physician and Sports Medicine Journal*, 1999.
- 2) Rudzki, JR. Matava, Mi, Paletta, GA; Complications of treatment of acromioclavicular and Sternoclavicular Joint Injuries. *Clinics in Sports Medicine*. Vol 22, No 2, April 2003

Competing Interests: None Declared

Funding: None Declared.

This article has been peer reviewed.

Correspondence to:

Barry Brenner MD PhD FACEP FCCP
 Professor of Emergency Medicine
 Professor of Internal Medicine
 Professor of Anatomy and Neurobiology
 Chairman of Emergency Medicine
 College of Medicine, #584
 University of Arkansas for Medical Sciences
 4301 West Markham St
 Little Rock AR 72205

e-mail: BrennerBarry@uams.edu