

The Brugada Syndrome: An Easily Identified and Preventable Cause of Sudden Cardiac Death

Raymond Farah, MD¹, Elias Nassir, MD², Rola Farah, MD³, Moshe Shai, MD⁴, Nathan Roguin, MD⁵

¹ Department of Emergency Medicine, ^{2, 4}Department of internal medicine, ⁵ Department of Cardiology, Nahariya Hospital, B. Rappaport Faculty of Medicine, Technion, Nahariya, Israel.

³ Department of Obstetrics and Gynecology, HaEmek Medical Center, Afula, Israel.

Abstract:

The authors describe two case of syncope with Brugada-type ECG. The pathophysiology of Brugada syndrome and current concepts of management are reviewed.

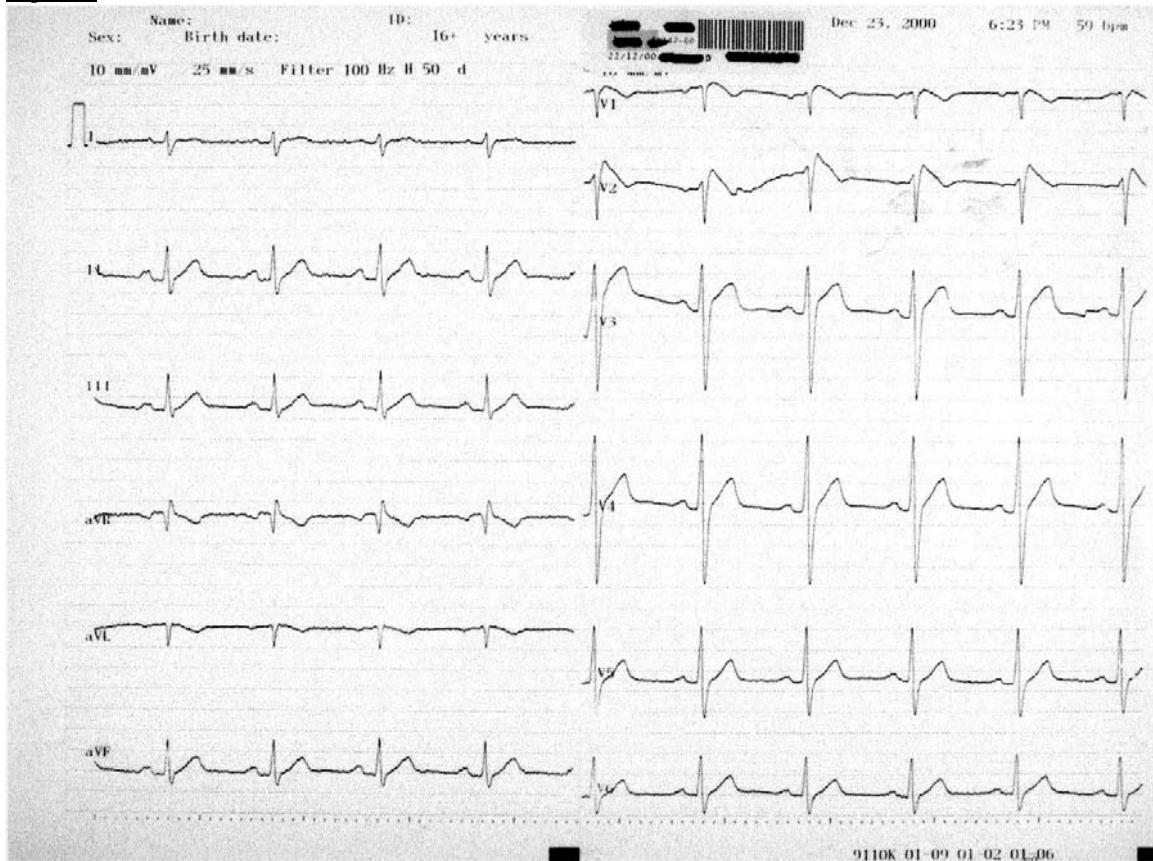
MeSH Words: Brugada syndrome, syncope, sudden death, ventricular arrhythmia, electrophysiologic study

Introduction

We report two cases of syncope in which the identification of Brugada – type ECG was made after the patient presented to the emergency department (ED). The diagnosis was suspected by ECG changes, after the characteristic pattern of right bundle branch block (RBBB) and ST segment elevation in lead V₁ through V₃.

Patients with cardiac causes of syncope have a much higher one-year mortality rate than patients with non cardiac causes about 20-30% against 5% for non cardiac syncope and 10% for syncope of unknown origin (1). Therefore, identifying and treating cardiac causes of syncope decrease morbidity and mortality. The

Figure 1



Brugada syndrome is characterized by syncope with or without sudden cardiac death (SCD) caused by polymorphic ventricular tachycardia and is identified by distinctive ECG changes. It is important that emergency physicians recognize this ECG sign marker for SCD.(2).

Case 1: A 45-year old man was brought to the emergency department for evaluation of palpitations, atypical chest pain and syncope. His past medical history was remarkable for palpitations with documented ventricular extrasystoles known for 4 years, controlled with propafenone.

There was no prior family history of SCD. He had no evidence of heart disease by echocardiography or exercise stress test. Physical examination was normal, blood pressure 122/70mmHg, pulse rate 60 beats/min (BPM), respiratory rate 16 breaths/min and temperature 36.6°C. Cardiac examination revealed no gallop, murmurs, or friction rub. Lungs were clear. Neurologic examination revealed no focal

deficits.

The ECG showed NSR at 60 per min, frontal plane QRS axis was +90 degree, PR interval 0.16, QT 0.40 sec, peculiar downsloping ST-segment elevation in lead V1 and V2 with a QRS morphology resembling a right bundle branch block (RBBB). Figure1.

Results of laboratory tests, including determination of serum electrolytes, serum glucose, creatine phosphate kinase (MB fraction) and troponin I, were within normal limits. Chest radiography was normal. Echocardiogram and Doppler examination were also normal. Holter tracing showed heart rate 50-80 BPM, no VT or VF. The patient underwent electrophysiological study,(EPS) where Brugada syndrome was recognized. The (EPS) demonstrated inducible VT/VF during programmed stimulation. The patient was discharged home with quinidine sulphate treatment 1500 mg/day, instead of an implantable cardioverter defibrillator (ICD) without further arrhythmias. EPS was performed

one month after treatment and again three years later, he remained VT/VF free.

Case 2: A 50 - year old man presented to the emergency department due to palpitation, high fever, chills, dysuria and syncopal episode with head trauma. His past medical history was remarkable only for benign prostatic hypertrophy and recurrent syncope. There was no history of coronary heart disease, diabetes, or hypertension and no prior family history of SCD. On arrival, the patient appeared in good general condition, was awake and alert. The initial vital signs were: blood pressure 115/60 mmHg, pulse rate 120 beats/min, respiratory rate 20 breaths/min and temperature 38.6°C. Physical examination revealed a forehead contusion and laceration without deformity. There was no jugular venous distention. Cardiac examination revealed no gallop, murmur or friction rub. The rest of the patient's examination was normal. The ECG showed a sinus tachycardia at a rate of 120 per min, RBBB with saddle-back type downsloping ST-segment elevation in leads V1 and V2. The ECG tracings were consistent with Brugada sign. (Figure 2). Laboratory analysis were within the normal range, including cardiac enzymes and troponin I. Urine examination revealed pyuria, urine culture subsequently revealed *Morganella Morganii* and blood culture was sterile.

The patient was treated with antipyretic and intravenous ofloxacin. His temperature and pulse rate improved. The Brugada pattern disappeared and the ECG normalized. The electrophysiological study (EPS) demonstrated inducible VT/VF during programmed stimulation. An automatic internal cardioverter defibrillator (AICD) was placed, and the patient was discharged home without any further arrhythmia for the last five years.

Discussion:

Cardiac syncope can be classified as being either structural or arrhythmogenic in origin and is one of the main causes of SCD in young adults. It is a rare condition and due to its mutating manner of presentation, it may be difficult to diagnose. Brugada syndrome, first described in 1992, is a syndrome consisting of syncopal episodes and/or sudden death in patients with a structurally normal heart and a

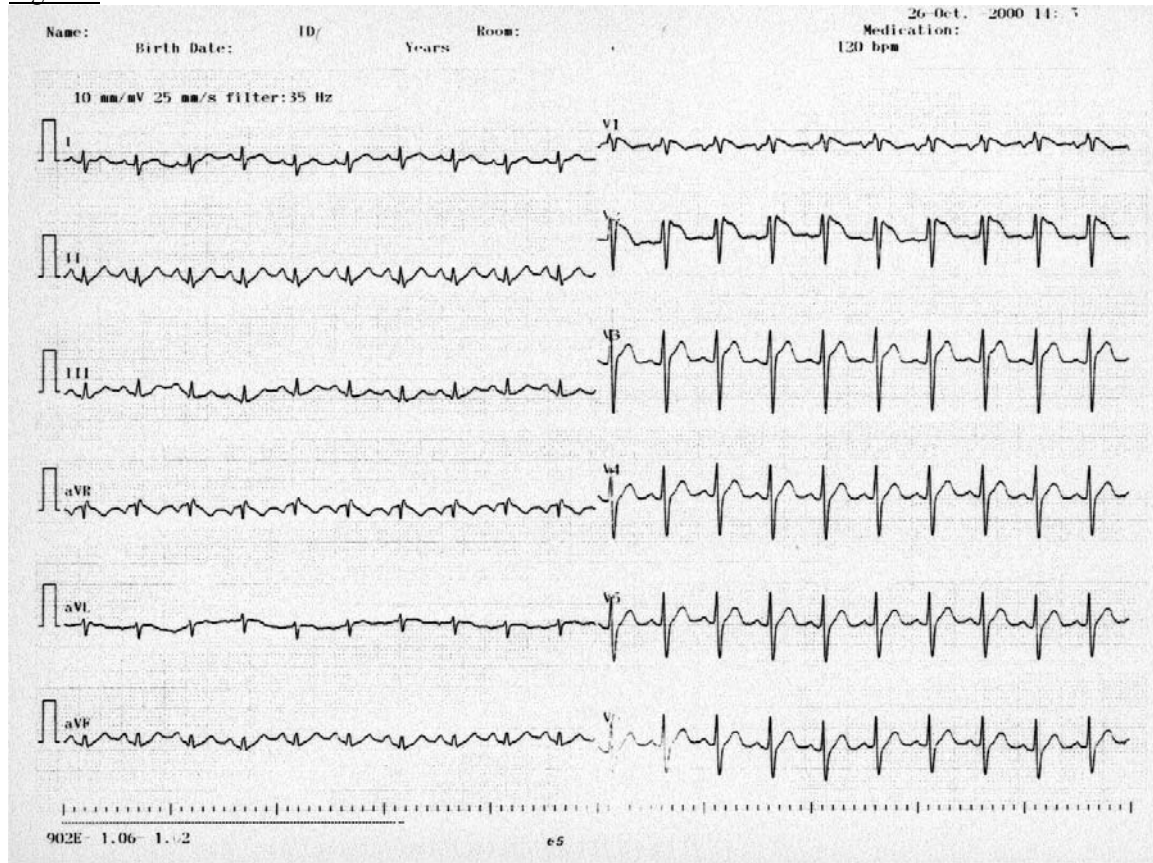
characteristic electrocardiogram displaying a pattern resembling right bundle branch block with a ST segment elevation in leads V1 to V3 (1). As in patients with long QT syndrome, the ECG changes and the ventricular electrical instability cannot be explained by structural heart disease, myocardial ischemia or electrolyte disturbances.

The syndrome can be inherited and predominantly affects males (2). The mechanism of this syndrome is an electrical cardiac illness secondary to mutation of SCN5A gene of chromosome 3 that has a dominant autosomic transmission pattern. The mutation occurs at the cardiac sodium channel and results in total loss of function of the sodium channel or in acceleration of the recovery from activation of the sodium channel (3). These mutations are thought to cause VT/VF through heterogeneity of the refractory period resulting from the presence of both normal and mutated sodium channels in the same tissue, or from the reduction in the number of functional sodium channels which would be expected to promote the development of phase 2 re-entrant arrhythmias (3). The downsloping ST-segment elevation is the result of a much earlier repolarization of the epicardial action potential. This caused by a more intense transient outward current 3 depression or loss of the action potential dome in RV epicardium creating a transmural voltage gradient that may be responsible for the ST-segment elevation observed in the Brugada syndrome (4). The channel dysfunction may be intermittent, and consequently so can the ECG abnormalities.

Different situations have been involved in the origin of ventricular arrhythmic events in patients with Brugada syndrome, including bradycardia, alcohol consumption, mental stress drugs and fever as in our second case. This may explain the role of fever as a trigger for syncope and Brugada sign in one of our patients (3,5).

Brugada syndrome occurs worldwide and has been estimated to account for 40%-60% of all cases of idiopathic VF in some countries in southeast Asia. It most commonly affects adult men, with the first arrhythmic event usually occurring during the fourth decade of life (3).

Figure 2



It is anticipated that the number of cases diagnosed will increase significantly as physician recognition of this disease increases. As in this case, ECG can make the diagnosis of Brugada syndrome. This disease should be considered in patients with right precordial lead ST-segment elevation that cannot be explained by ischemia, electrolyte or metabolic disorders central or autonomic nervous system disorders or early repolarization syndrome. It should be considered in patients with a positive family history of SCD, who present to ED with cardiac syncope, but have a normal ECG at rest.

The standard treatment of Brugada syndrome currently consists of implantation of an automatic internal cardioverter defibrillator (AICD). To date, there have only been two randomized clinical trials that compared AICD with drug therapy (Beta blockers). One study found that the incidence of arrhythmic events was similar in both groups (6). The other study showed that EP-guided therapy with class Ia agents is a reasonable, safe and effective approach for the long-term management of

patients with idiopathic VF with or without Brugada syndrome, like our patient (7). However, only patients in the AICD group were protected against SCD (6). AICD has been shown to reduce the 10-year mortality rate from the disease to 0%.

This syndrome should be considered in the ED on the basis of history and family history of SCD, as a normal resting ECG does not rule out Brugada. Consultation with a cardiologist specializing in electrophysiology should be obtained, because without AICD treatment the incidence of sudden cardiac death in these patients is high.

References:

1. Kapoor WN. Approach to the patient with syncope: Goldman L, Braunwald E, eds. Primary Cardiology 1st ed. Philadelphia, PA: WB Saunders; 1998: 144-154.
2. Corrado D, Buja G, Basso C, Nava A, Thieme G. What is the Brugada syndrome? *Cardiol Rev* 1999 Jul – Aug; (4): 191-5.
3. Chen Q, Kirsch GE, Zhang D, et al. Genetic basis and molecular mechanisms for idiopathic ventricular fibrillation. *Nature*. 1998; 392: 298-296.
4. Yan GX, Antzelevitch C. Cellular basis for the Brugada syndrome and other mechanisms of arrhythmogenesis associated with ST- segment elevation. *Circulation* 1999 Oct 12;100(15):1660-1666.
5. Gonzalez JM, Hernandez A, Garcia A, et al. Recurrent ventricular fibrillation during a febrile illness in a patient with the Brugada syndrome. *Rev. Esp Cardiol* 2000; 53 (5) : 755-7.
6. Nademanee K, Veerakul G, Nimmanit S, et al. Arrhythmogenic marker for the sudden unexplained death syndrome in Thai men. *Circulation*. 1997;96:2595-2600.
7. Belhassen B, Viskin S, Fish R, Glick A, Setbon I, Eldar M. Effects of electrophysiologic – guided therapy with class IA antiarrhythmic drugs on the long-term outcome of patient with idiopathic ventricular fibrillation with or without the Brugada syndrome. *J Cardiovasc Electrophysiol*. 1999;10(1):1301-12.

Competing Interests: None Declared
Funding: None

This manuscript has been peer reviewed.

Correspondence:

Raymond Farah MD,
 Emergency Department, Nahariya Hospital.
 Nahariya, Israel. FAX 972(4) 9875114

email: raymondfarah@hotmail.com.