

---

## Introduction to Emergency Ultrasound

Tom Ashar, MD\*

*\*Director of Emergency Ultrasound, Department of Emergency Medicine,  
Newark Beth Israel Medical Center, New York*

### Abstract:

Emergency ultrasound is a rapidly evolving technology. This article, the first in a series, discusses the unique role of emergency bedside ultrasound. Emergency ultrasound applications and limitations are outlined, as well as educational and administrative requirements.

**MeSH Words:** emergency ultrasound, residency training, education

### Introduction to Emergency Ultrasound

Emergency ultrasound has arrived. Initially a technology utilized in the 1980's for the evaluation of the trauma patient (the FAST exam)<sup>1,2,3</sup> ultrasound in the hands of emergency physicians has rapidly expanded to include the imaging of almost every imaginable body part for a variety of complaints.

This article, the first in a series, will focus on the role of emergency ultrasound as it is practiced today in the United States. Future issues will describe specific applications of emergency ultrasound, both basic and advanced. The focus will be practical information for the practitioner to utilize at the bedside, as well as providing relevant supporting literature.

### What is Emergency Ultrasound?

The goal of emergency ultrasound is to *answer a focused clinical question in a timely manner*. Unlike radiologists and sonographers,

emergency physicians do not seek to perform a comprehensive and time consuming evaluation of an organ or body system. Rather, ultrasound as utilized in emergency departments in the United States is an extension of the physical exam – a diagnostic and procedural aide.

Whereas a right upper quadrant (RUQ) ultrasound performed in the radiology suite would evaluate the gall bladder, the liver, the pancreas and other RUQ structures, that performed in the emergency department (ED) is distilled to the relevant clinical dichotomy: Does

**Table 1. Basic 6 Applications**

Application	Focused Clinical Question	Sonographic Finding
Cardiac	Is there Cardiac Motion? Is there a pericardial effusion?	Recognize cardiac motion. Identify pericardial fluid.
Biliary	Is there acute cholecystitis?	Identify GB and GB wall thickness, presence of gallstones, sonographic Murphy's sign*, common bile duct (CBD) dilatation.
Renal	Is there hydronephrosis?	Recognize hydronephrosis (dilation of renal pelvis)
Abdominal Aorta	Is the abdominal aorta enlarged?	Measure abdominal aorta from diaphragm to bifurcation.
Intrauterine Pregnancy	Is there a live intrauterine pregnancy?	Identify a yolk sac or a fetal pole. Document fetal heart if present.
Trauma	Is there hemoperitoneum? Is there a hemopericardium?	Anechoic (black) fluid stripe in hepatorenal / splenorenal space or pelvis. Identify pericardial fluid (see above)

\*Sonographic Murphy's Sign – gallbladder tenderness under direct pressure of ultrasound transducer.

the patient have acute cholecystitis? Although with increased operator experience other pathology may be identified, it is the ability to *answer an important clinical question in a few minutes spent at the bedside* that is the hallmark of emergency ultrasound.

The second feature that differentiates ultrasound performed by emergency physicians is our role in *interpreting the clinical relevance* of the studies performed. While both the emergency physician and ultrasound technician can identify hydronephrosis of the left kidney, only the emergency physician determines if that finding adequately explains the patients' clinical presentation or whether further work-up is warranted.

#### Advantages of Emergency Ultrasound

In general, the advantages of emergency ultrasound include the lack of ionizing radiation, real-time imaging and the fact that it is non-invasive.

Some specific advantages to ultrasound as performed by emergency physicians are as follows:

- Rapidly evaluates a number of critical clinical scenarios from acute shortness of breath to the patient with unexplained shock.<sup>4,5,6,7,8</sup>
- Ease of use: multiple investigators have shown that, with only minimal training, emergency physicians can perform many of the required ultrasound examinations<sup>9,10,11</sup>.
- Performed at the bedside: the unstable patient does not have to leave the emergency department during the critical period of initial evaluation.
- Save time and money by decreasing emergency department length-of-stay (LOS) and other costly imaging for a variety of diagnoses from threatened abortion<sup>12,13,14</sup> to renal colic<sup>15,16,17,18</sup>.

#### Applications of Emergency Ultrasound

The clinical applications of emergency ultrasound are continually developing. While the practitioner new to ultrasound may focus on

**Table 2. Advanced Applications**

Application	Clinical Question	Sonographic Finding
Advanced Cardiac	Is there evidence of acute ischemic heart disease?	regional wall motion abnormality?
Advanced Trauma	Is there hemo/pneumo thorax? Obtain venous access.	Hemo/pneumo-thorax. Landmarks for venous access.
Advanced Gynecologic	Is there ovarian pathology?	ovarian torsion, ovarian masses.
Deep venous thrombosis	Is there a DVT?	Demonstrate compression of femoral and popliteal veins.
Testicular	Is there testicular torsion?	Identify normal testicular anatomy, epididymitis, hydrocele, and testicular torsion.
Musculoskeletal	Evaluate musculoskeletal complaints, perform arthrocentesis	fractures, soft tissue pathology, joint effusions.
Orbital	Is there retinal detachment? Is there elevated ICP?	Retinal detachment. Measure optic nerve sheath size to estimate ICP.

**Table 3. Ultrasound Guided Procedures**

Application	Sonographic Finding
Central Line	Identify correct venous vessels.
Thoracentesis Paracentesis Pericardiocentesis	Identify area of greatest pleural, peritoneal or pericardial fluid for puncture site
Foreign Body Localization	Localize presence of wound foreign bodies
Cellulitis / Abscess	presence of fluid collection in evaluation of soft tissue infections.
Fracture reduction	proper skeletal alignment after manipulation
Bladder evaluation	Estimate bladder volume. Localize ideal site for bladder aspiration.

identifying hemoperitoneum in the trauma patient, studies show that more experienced emergency physicians are performing bedside cardiac echocardiograms with accuracies approaching that of cardiologists<sup>19,20</sup>.

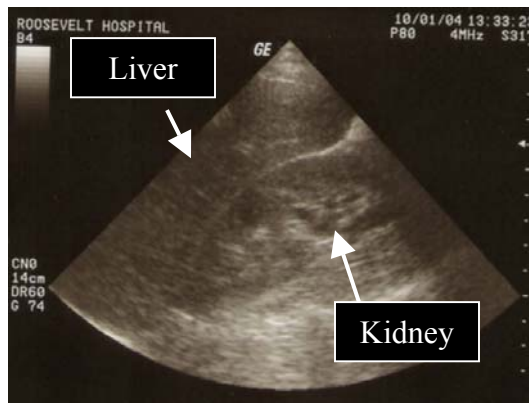The American College of Emergency Physicians (ACEP), in guidelines published in 2001<sup>21</sup>, classified emergency ultrasound into what has come to be known in the United States as the 'Basic 6' Applications, 'Advanced

Applications', and 'Procedural Applications'. (see attached tables). The accepted 'Basic 6' applications are:

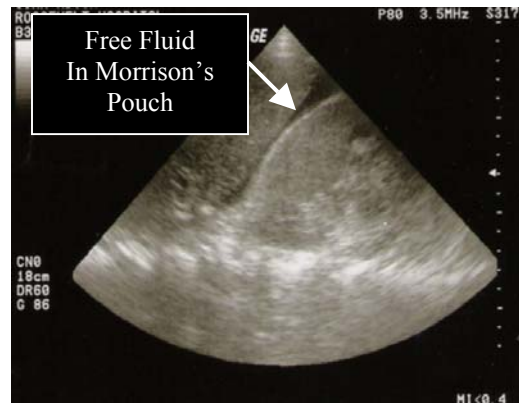- 1) Identify intra-abdominal or pericardial fluid in trauma.
- 2) Identify cardiac standstill / asystole.
- 3) Identify cholecystitis.
- 4) Identify an abdominal aortic aneurysm.
- 5) Identify hydronephrosis.
- 6) Identify an intra-uterine pregnancy.

## Case Scenarios in Emergency Ultrasound

### Case I



(a)



(b)

**Case History:** 29 year-old female is brought to the ED after motor vehicle collision. Vital signs significant for HR = 119 bpm and BP = 95/60 mmHg. Physical exam is significant for seat belt abrasions over chest and lower abdomen.

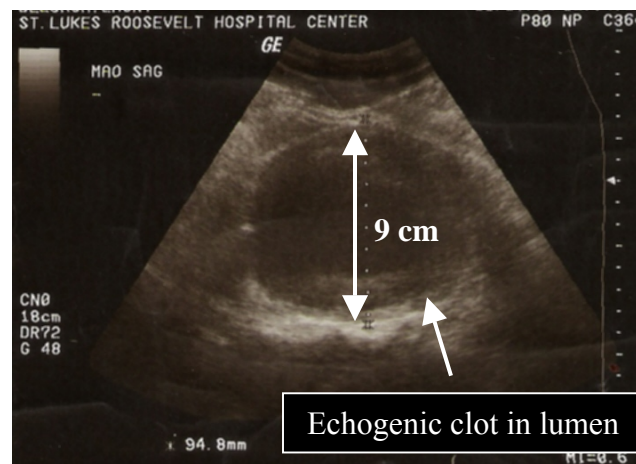
**Sonographic Findings:** With the 3.5MHz abdominal transducer placed in the sagittal plane in the right upper quadrant, anterior axillary line, the normal interface between liver and right kidney is viewed in image (a). In image (b) a dark stripe of abdominal fluid (likely

hemoperitoneum in the setting of abdominal trauma) is seen in the hepatorenal space, also known as Morrison's Pouch.

**Presumptive diagnosis:** hemoperitoneum

**Significance:** In the setting of an unstable trauma patient, the finding of free abdominal fluid on the FAST exam is an indication to proceed directly to definitive surgical management.

### Case II



**Case History:** 79 year-old man is found unresponsive at home. In the ED, vital signs were significant for a heart rate of 109 bpm and a blood pressure of 94/52. There is no evidence of trauma. No family was available to provide any medical history.

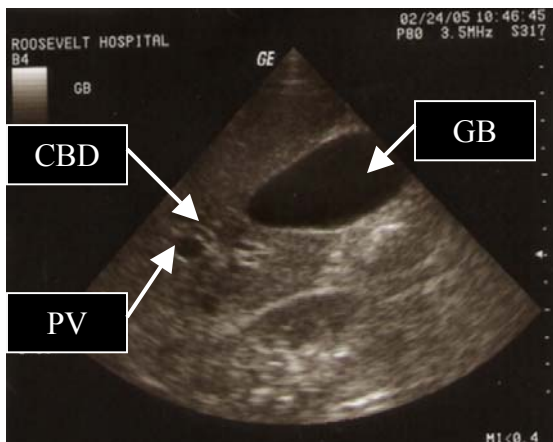
**Sonographic Findings:** With the 3.5MHz abdominal transducer placed in the transverse plane above the umbilicus, the above image shows an abdominal aorta with a transverse external diameter of 9.4 cm (normal aortic

diameter < 3cm). Echogenic ('white' on ultrasound) clot is seen surrounding the anechoic ('black') aortic lumen.

**Presumptive diagnosis:** ruptured AAA

**Significance:** Ultrasound is a useful adjunct in the approach to the patient with shock of unknown etiology. Whether the cause is a ruptured AAA, a pulmonary embolus, cardiogenic shock, or cardiac tamponade ultrasound provides vital information rapidly and at the bedside.

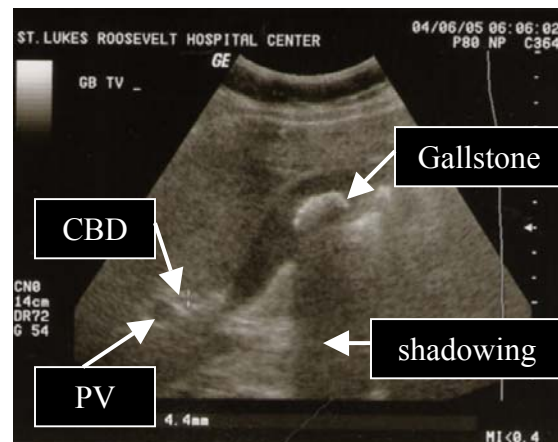
### Case III



(a)

**Case History:** A 32 year-old women presents with epigastric pain and vomiting 1 hour after eating. She reports a similar episode of 'food poisoning' 3 weeks ago that resolved spontaneously. On physical exam, she is afebrile, and her abdomen is obese with slight epigastric tenderness. Otherwise, physical exam is unremarkable.

**Sonographic Findings:** With the 3.5MHz abdominal transducer placed in the sagittal plane in the right upper quadrant, image (a) shows a normal gallbladder (GB), with the common bile duct (CBD) as the structure above the portal vein (PV). In our patient, image (b), there is the

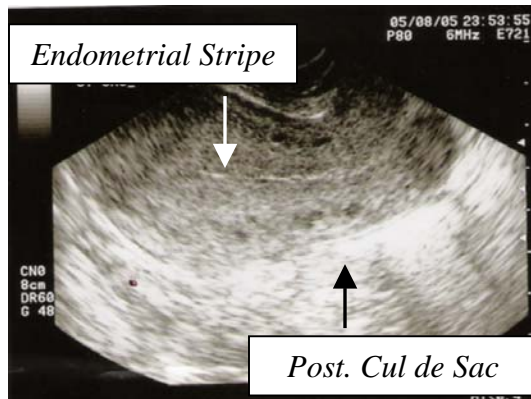


(b)

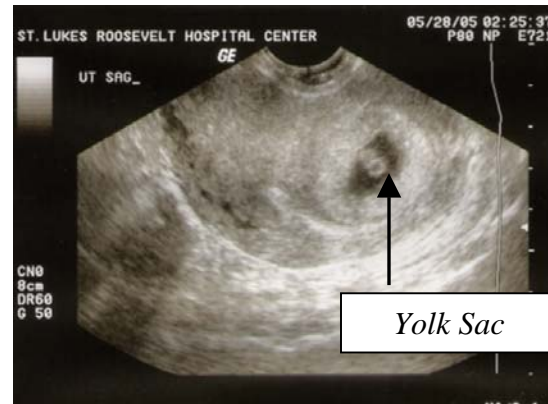
presence of a large gallstone in the gallbladder. Acoustic shadowing may be seen posterior to the gallstone. The wall of the gallbladder is not thickened (less than 3mm) and there is no pericholecystic fluid. Sonographic Murphy's sign, tenderness over the gallbladder with compression with the ultrasound transducer, is notably absent.

**Presumptive diagnosis:** Biliary colic.

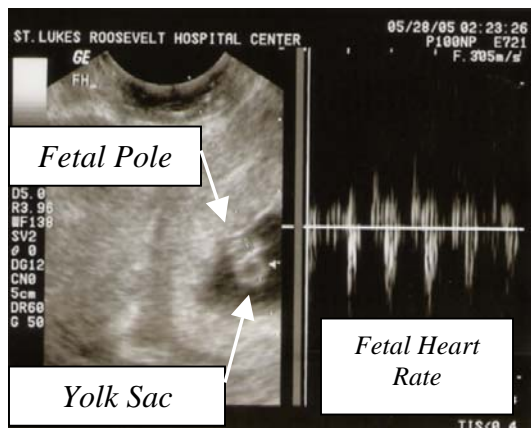
**Significance:** Emergency ultrasound can be readily utilized to identify the spectrum of biliary disease, from biliary colic to acute cholecystitis.

**Case IV**

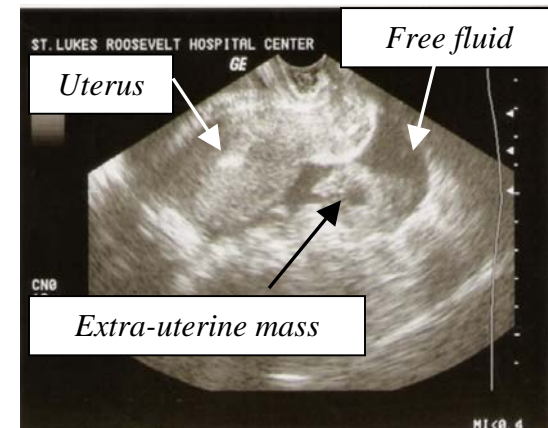
(a)



(b)



(c)



(d)

**Case History:** 23 year-old woman presents with lower abdominal pain and slight vaginal bleeding for 2 days. Her last menstrual period was 6 weeks ago, but she reports a history of irregular menses. On physical exam, all vital signs are within normal, the abdomen is thin and soft, and pelvic exam is significant for a closed os, trace blood in the vaginal vault and no adnexal masses or tenderness. Urine pregnancy test is positive.

**Sonographic Findings:** Using a 7.5Mhz endovaginal probe in the sagittal orientation, image (a) demonstrates a uterus without evidence of an IUP. The presence of the endometrial stripe ensures to the image reviewer that the endometrium is adequately visualized. No free pelvic fluid is seen in the posterior cul-de-sac.

Image (b) demonstrates an intrauterine yolk sac, considered definitive proof of an IUP. This embryonic nutritive structure is first seen on transvaginal ultrasound at 5-6 weeks gestational

age. On magnified imaging (c), fetal cardiac activity is demonstrated in the fetal pole adjacent to the yolk sac.

Image (d) from another patient shows a complex adnexal structure and free fluid in the pelvis – findings that are highly suspicious for an ectopic pregnancy.

**Presumptive diagnosis:**

Image (a): no definitive IUP

Image (b): IUP (no fetal heart)

Image (c): live IUP (positive fetal heart)

Image (d): high suspicion for ectopic pregnancy.

**Significance:** Emergency ultrasound in the first trimester of pregnancy allows the emergency physician to rapidly and accurately evaluate the patient at risk of ectopic pregnancy.<sup>12-14</sup>

### Limitations of Emergency Ultrasound

The quality of the imaging and information gathered depends upon the experience of the sonographer. Studies have shown that with limited training (sometimes no more than one hour of instruction), emergency physicians attain accuracy in placing ultrasound-guided central lines<sup>9,22,23</sup>, identifying hemoperitoneum<sup>24</sup> and other pathology<sup>5,8</sup>. Physicians new to this technology understand the difficulty in obtaining and interpreting quality ultrasound images.

Other challenges are financial and political: purchasing an ultrasound machine, financing machine maintenance, credentialing emergency department staff within the hospital, and obtaining the time and money for training. Although surmountable, all of these concerns may prove difficult to overcome.

### Conclusion

Ultrasound performed by emergency physicians is rapidly becoming 'standard of care'. With the recent mandatory inclusion of ultrasound training as part of the emergency medicine residency core curriculum<sup>25,26,27</sup> and multiple studies showing the improvement in patient care<sup>28,29</sup>, it is a skill that all of us will need to eventually adopt.

The scope of emergency ultrasound is also developing. From accepted uses such as trauma to the less conventional role in estimating intracranial pressure<sup>30</sup>, there is no doubt that ultrasound is a rapid and safe diagnostic and procedural tool.

### References

- <sup>1</sup> Halbfass, H. J., B. Wimmer, et al. (1981). "Ultrasonic diagnosis of blunt abdominal injuries." Fortschr Med **99**(41): 1681-5.
- <sup>2</sup> Wening, J. V. (1989). "Evaluation of ultrasound, lavage, and computed tomography in blunt abdominal trauma." Surg Endosc **3**(3): 152-8.
- <sup>3</sup> Tayal, V. S., M. A. Beatty, et al. (2004). "FAST (focused assessment with sonography in trauma) accurate for cardiac and intraperitoneal injury in penetrating anterior chest trauma." J Ultrasound Med **23**(4): 467-72.
- <sup>4</sup> Rose, J. S., A. E. Bair, et al. (2001). "The UHP ultrasound protocol: a novel ultrasound approach to the empiric evaluation of the undifferentiated hypotensive patient." Am J Emerg Med **19**(4): 299-302.
- <sup>5</sup> Jang, T., C. Aubin, et al. (2004). "Ultrasonography of the internal jugular vein in patients with dyspnea without jugular venous distention on physical examination." Ann Emerg Med **44**(2): 160-8.
- <sup>6</sup> Blaivas, M. (2001). "Incidence of pericardial effusion in patients presenting to the emergency department with unexplained dyspnea." Acad Emerg Med **8**(12): 1143-6.
- <sup>7</sup> Yahia, S., N. E. Brodyn, et al. (1996). "Emergent use of echocardiography in a post-myocardial infarction patient with acute dyspnea." Am J Emerg Med **14**(1): 33-6.
- <sup>8</sup> Jones, A. E., V. S. Tayal, et al. (2004). "Randomized, controlled trial of immediate versus delayed goal-directed ultrasound to identify the cause of nontraumatic hypotension in emergency department patients." Crit Care Med **32**(8): 1703-8.
- <sup>9</sup> Kuhn, M., R. L. Bonnin, et al. (2000). "Emergency department ultrasound scanning for abdominal aortic aneurysm: accessible, accurate, and advantageous." Ann Emerg Med **36**(3): 219-23.

- <sup>10</sup> Rowland, J. L., M. Kuhn, et al. (2001). "Accuracy of emergency department bedside ultrasonography." Emerg Med (Fremantle) **13**(3): 305-13.
- <sup>11</sup> Miller, A. H., B. A. Roth, et al. (2002). "Ultrasound guidance versus the landmark technique for the placement of central venous catheters in the emergency department." Acad Emerg Med **9**(8): 800-5.
- <sup>12</sup> Burgher, S. W., T. K. Tandy, et al. (1998). "Transvaginal ultrasonography by emergency physicians decreases patient time in the emergency department." Acad Emerg Med **5**(8): 802-7.
- <sup>13</sup> Shih, C. H. (1997). "Effect of emergency physician-performed pelvic sonography on length of stay in the emergency department." Ann Emerg Med **29**(3): 348-51; discussion 352.
- <sup>14</sup> Blaivas, M., P. Sierzenski, et al. (2000). "Do emergency physicians save time when locating a live intrauterine pregnancy with bedside ultrasonography?" Acad Emerg Med **7**(9): 988-93.
- <sup>15</sup> Henderson, S. O., R. J. Hoffner, et al. (1998). "Bedside emergency department ultrasonography plus radiography of the kidneys, ureters, and bladder vs intravenous pyelography in the evaluation of suspected ureteral colic." Acad Emerg Med **5**(7): 666-71.
- <sup>16</sup> Rosen, C. L., D. F. Brown, et al. (1998). "Ultrasonography by emergency physicians in patients with suspected ureteral colic." J Emerg Med **16**(6): 865-70.
- <sup>17</sup> Noble, V. E. and D. F. Brown (2004). "Renal ultrasound." Emerg Med Clin North Am **22**(3): 641-59.
- <sup>18</sup> Salen PN, Hennelly M, Kelleman A, et al. Emergency physician bedside ultrasound decreases length of stay, intravenous usage, and patient charges in the evaluation of ureteral colic compared with computed tomography and intravenous pyelography [abstract]. Ann Emerg Med. 2000;36:S20.
- <sup>19</sup> Randazzo, M. R., E. R. Snoey, et al. (2003). "Accuracy of emergency physician assessment of left ventricular ejection fraction and central venous pressure using echocardiography." Acad Emerg Med **10**(9): 973-7.
- <sup>20</sup> Jones, A. E., V. S. Tayal, et al. (2003). "Focused training of emergency medicine residents in goal-directed echocardiography: a prospective study." Acad Emerg Med **10**(10): 1054-8.
- <sup>21</sup> (2001). "American College of Emergency Physicians. ACEP emergency ultrasound guidelines-2001." Ann Emerg Med **38**(4): 470-81.
- <sup>22</sup> Hind, D., N. Calvert, et al. (2003). "Ultrasonic locating devices for central venous cannulation: meta-analysis." Bmj **327**(7411): 361.
- <sup>23</sup> Denys, B. G. and B. F. Uretsky (1991). "Anatomical variations of internal jugular vein location: impact on central venous access." Crit Care Med **19**(12): 1516-9.
- <sup>24</sup> Shackford, S. R., F. B. Rogers, et al. (1999). "Focused abdominal sonogram for trauma: the learning curve of nonradiologist clinicians in detecting hemoperitoneum." J Trauma **46**(4): 553-62; discussion 562-4.
- <sup>25</sup> [http://www.acgme.org/acWebsite/RRC\\_110/110\\_guidelines.asp#res](http://www.acgme.org/acWebsite/RRC_110/110_guidelines.asp#res)
- <sup>26</sup> Counselman, F. L., A. Sanders, et al. (2003). "The status of bedside ultrasonography training in emergency medicine residency programs." Acad Emerg Med **10**(1): 37-42.
- <sup>27</sup> Moore, C. L., S. Gregg, et al. (2004). "Performance, training, quality assurance, and reimbursement of emergency physician-performed ultrasonography at academic medical centers." J Ultrasound Med **23**(4): 459-66.
- <sup>28</sup> Bassler, D., E. R. Snoey, et al. (2003). "Goal-directed abdominal ultrasonography: impact on real-time decision making in the emergency department." J Emerg Med **24**(4): 375-8.
- <sup>29</sup> Kobal, S. L., S. Atar, et al. (2004). "Hand-carried ultrasound improves the bedside cardiovascular examination." Chest **126**(3): 693-701.

---

<sup>30</sup> Tsung, J. W., M. Blaivas, et al. (2005). "A rapid noninvasive method of detecting elevated intracranial pressure using bedside ocular ultrasound: application to 3 cases of head trauma in the pediatric emergency department." Pediatr Emerg Care **21**(2): 94-8.

**Competing Interests:** None Declared

**Funding:** None Declared.

This article has been peer reviewed.

---

**Correspondence to:**

Dr. Tom Ashar,  
Department of Emergency Medicine,  
Newark Beth Israel Medical Center, 201 Lyons  
Avenue at Osborne Avenue  
Newark, NJ 07112

**Email:** tomashar@gmail.com