

---

# Ultrasound-Guided Peripheral Venous Access

Jessica R. Goldstein MD RDMS<sup>a</sup>

<sup>a</sup> *MetroHealth Medical Center, Cleveland OH, USA*

## Abstract

Patients in whom peripheral venous access cannot be obtained with traditional techniques pose a challenge to emergency departments across the world. Alternative access sites include central lines and deeper peripheral veins. Increased access to portable ultrasound machines makes ultrasound-guided peripheral venous access an increasingly popular option. This technique can be learned by physicians and nurses in the emergency department. This article reviews basic venous anatomy, the basics of ultrasound technology, and techniques to cannulate a deep vein using ultrasound guidance.

**MeSH Words:** Ultrasound, Peripheral, Venous, Access, Intravenous

## Introduction

Patients in whom peripheral venous access cannot be obtained with traditional techniques pose a challenge to emergency departments across the world. Alternative access sites include central lines and deeper peripheral veins. Increased access to portable ultrasound machines makes ultrasound-guided peripheral venous access an increasingly popular option [1-5]. This technique can be learned by physicians and nurses in the emergency department [2-4].

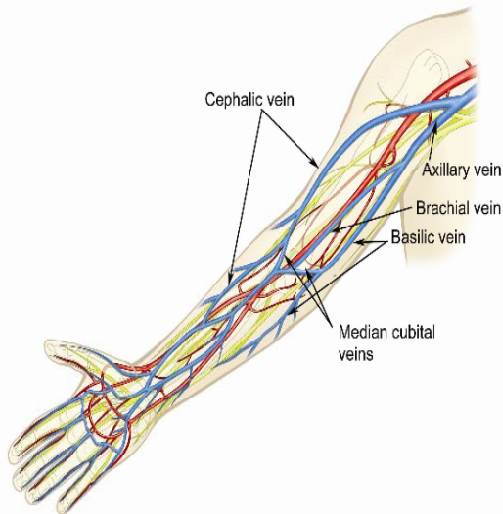
## Objectives

1. To understand peripheral venous anatomy
2. To become familiar with the basics of an ultrasound machine
3. To understand ultrasound orientation
4. To become familiar with equipment required for ultrasound guided IVs
5. To learn the steps required to cannulate a deep vein

## Anatomy

Understanding peripheral venous anatomy is the first requirement in attempting peripheral venous access. The three main options for deep veins in

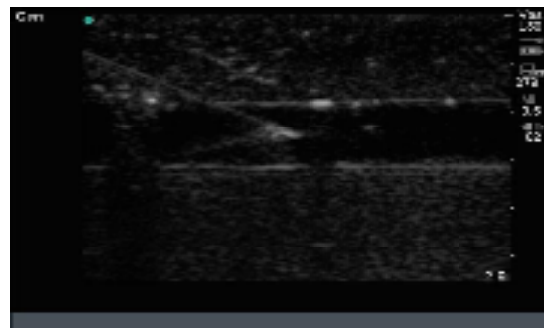
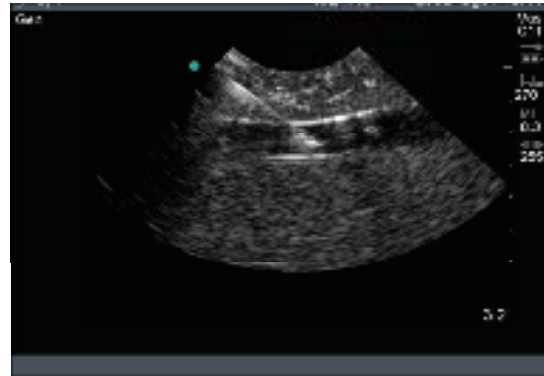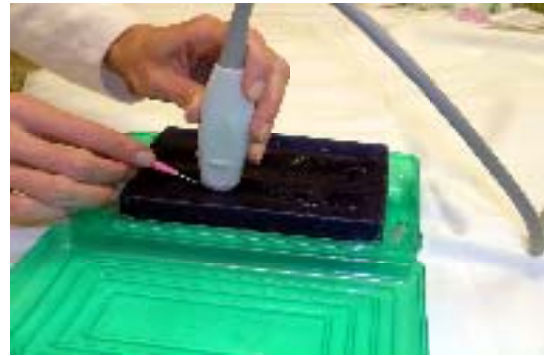
the arm are the 1. deep brachial vein 2. basilic vein and 3. cephalic vein (figure 1). More distal veins such as the median antebrachial and accessory cephalic can sometimes be identified on ultrasound when they are not visible on the skin surface and can also be used.



*Figure 1. Key anatomy in the upper extremity. Note the course of the basilic vein from the ulnar forearm through the antecubital fossa along the medial side of the upper arm. The paired median cubital veins connect the cephalic and basilic veins. The brachial vein parallels the brachial artery. The cephalic vein tends to be smaller than the basilic and brachial vein and runs along the center of the biceps muscle.*

## Ultrasound basics

Ultrasound machines vary in their appearance and modalities, but the functions necessary for peripheral venous access are common to most machines. Access to a high frequency transducer is required. Most hospitals utilize a linear high frequency transducer, but some sonographers prefer a curvilinear transducer (figure 2). As transducer frequency increases, image resolution improves but at the expense of the depth of skin penetration. Peripheral veins should be visualized within the limitations of depth permitted by a high frequency transducer.



*Figure 2 A-D. Linear and curvilinear transducers and corresponding ultrasound images on a practice gel for ultrasound-guided vascular access.*

### Maximizing your image

Ultrasound machines have preset functions for vascular scanning which give a starting point to scan the average patient. While the adjustments available vary from a few to an entire keyboard, the two basic functions to maximize the screen image are the gain and depth functions. Fluid filled structures such as veins should appear black or anechoic, void of echoes. Adjust the gain until there is slight fill-in with echoes, or white flecks, in the vein. The soft tissue surrounding the veins should also be visible so that fascial planes and nerves surrounding the veins are easily seen. Depth should be adjusted so that the view of target structures is maximized while allowing structures posterior to the target to also be seen (figure 3).

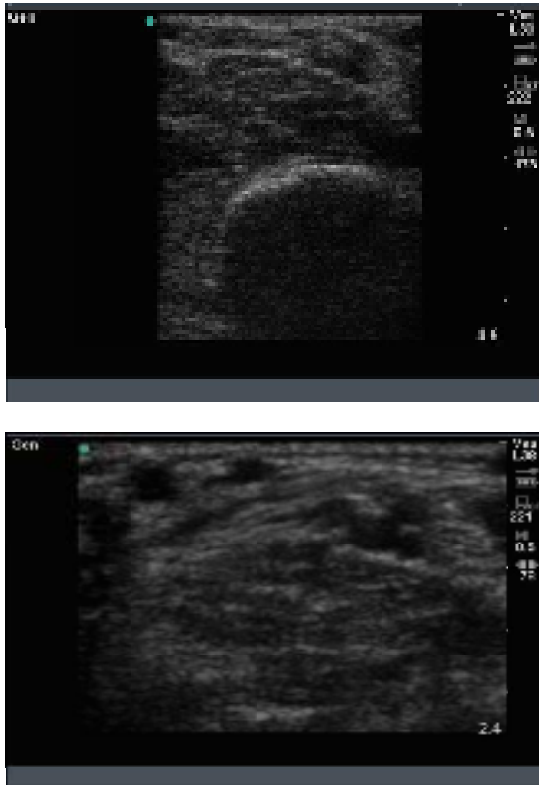

Figure 3A and B. Comparison of two images for depth: A. The depth is set too shallow. B. The depth is set appropriately so that the potential targets are larger on the ultrasound screen. The gain is set appropriately to see the adjacent fascicles of the median nerve.

### Ultrasound orientation

One of the most difficult but critical concepts when using ultrasound is understanding the relationship of transducer orientation and the ultrasound screen. Every ultrasound transducer has an indicator which corresponds to a trademarked icon on the ultrasound screen. The location of the indicator should be recognized at all times. If there is ever any confusion which side of the transducer has the indicator, apply gel on one side of the transducer face and look at the image on the screen. If the screen is active on the left then the indicator is on the same side as the gel. If the screen is active on the right then the indicator is on the opposite side as the gel (figure 4).

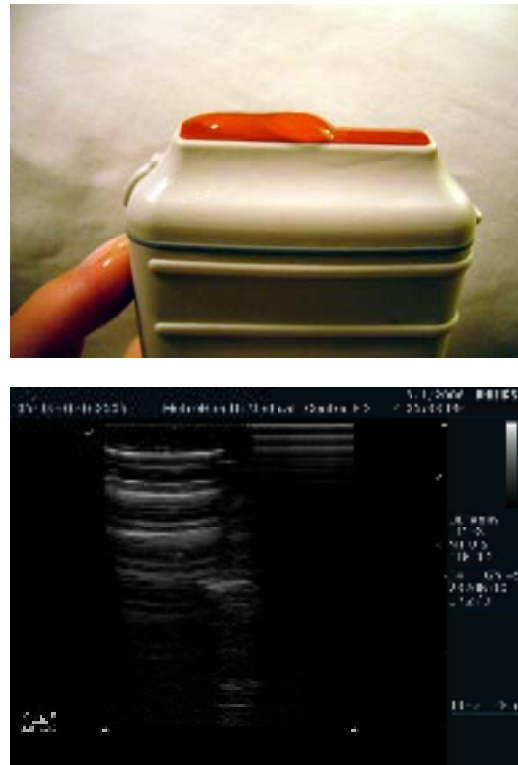


Figure 4A and B. Linear transducer with gel ipsilateral to the indicator and corresponding ultrasound image.

When scanning for vessels in short axis, the indicator should be located to the patient's right so that the left side of the ultrasound screen corresponds to the left side of the transducer. Any movement of the transducer in the horizontal plane will parallel the same movement on the ultrasound screen. When following

vessels in long axis, the location of the indicator is a preference of the sonographer. If the indicator is pointed distally, the needle will come across the screen from the upper right to the lower left. If the indicator is pointed proximally, the needle will come across the screen from the upper left to the lower right.

### How to select an appropriate vein

Selecting an appropriate vein is critical to the success and longevity of the ultrasound-guided peripheral intravenous (IV) line. The first step is distinguishing a vein from an artery. A vein is easily compressible with anterior-posterior pressure from the transducer. Arteries will also compress if enough pressure is applied, but arteries will pulsate with minimal compression. While not essential, color flow can be used to distinguish veins from arteries. Augmentation occurs when compression is applied distal to the vein of interest (figure 5). Flow through the vein, represented as color with color flow, is increased because the blood is forced to move proximally. Arteries do not augment with color flow.

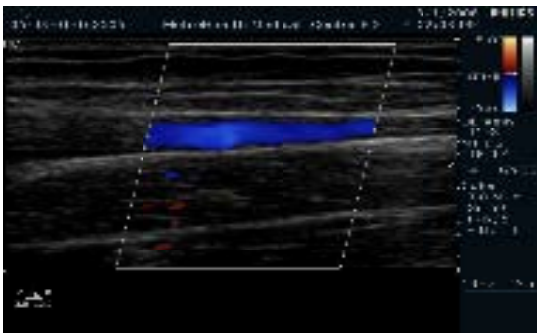
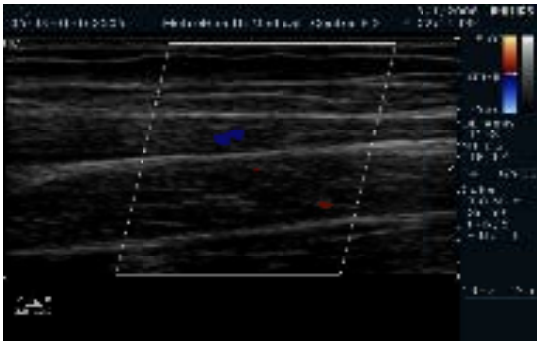


Figure 5 A and B. The basilic vein demonstrates augmentation when it is compressed distally. Color flow is increased from image A to image B.

### Equipment needed

Selection of the angiocatheter size has been a subject of debate in the emergency medicine community. The least expensive choice is a two-inch angiocatheter. Rates of infiltration when using these catheters are estimated at eight percent but may be even higher [4]. The minimum length of catheter inside the vein to prevent infiltration is multi-factorial: depth of the vein, proximity to the flexor crease and contracting muscles, and possibly others. Sandhu and Sidhu advocate obtaining access with a needle first and proceeding with the Seldinger technique to place a catheter longer than two inches inside the vein so that a patient may move his or her arm without forcing the catheter out of the vein [6]. These set-ups are obviously more expensive and long-term complications have not been studied.

Proceeding with aseptic versus sterile technique is also inconsistent in the literature [3,4,6]. Minimizing contact of the needle with gel and the transducer is intuitive but difficult for novice users. Prepping the skin for any IV line when blood cultures are taken must follow hospital standards. If sterile preparations are needed, commercially available transducer covers and sterile gel is available. One can also use a sterile glove with any sterile packaged water-based gel.

Consider using lidocaine without epinephrine when you are first trying his procedure. Be sure to not use epinephrine as your targets will disappear due to vasoconstriction.

### Technique

Several techniques exist for ultrasound-guided peripheral venous access. The first decision is whether to use a two-person approach or a one-

person approach. Having two people, one inserting the IV and one holding the transducer, requires less coordination for the person inserting the IV. The downside is that the procedure requires an extra person who is not always available in a busy emergency department and who may have little familiarity with ultrasound. Mechanical guides have little role in assisting peripheral venous access because the static angle of a mechanical guide does not allow for the variability in depth and course of peripheral veins.

The next set of steps can be remembered with the acronym LAMP: locate, align, mark, and puncture (LAMP) [7]. Location of the target vein begins with proper set-up. The ultrasound screen should be placed in the same line of sight as the target vein (figure 6). The patient's arm should be propped up with towels or on a procedural tray to facilitate easy entry of the needle through the skin. A tourniquet is placed close to the axilla to allow for selection of veins proximal to the antecubital fossa. Scan for an appropriate vein with either the dominant or non-dominant hand.

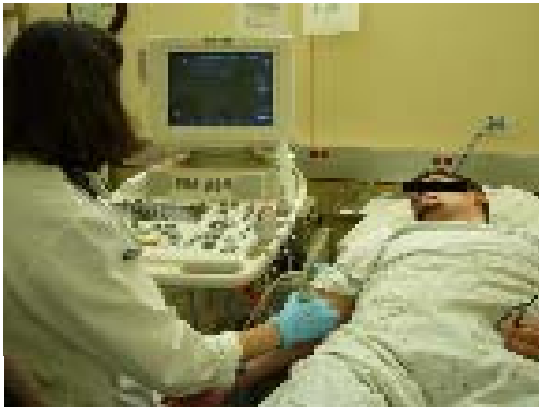

Figure 6. Proper set-up has the sonologist facing both the target and the ultrasound screen.

An ideal vein is large, superficial, isolated and remote from the flexor crease. Unfortunately these traits are not often seen (figure 7). In short axis to the target vein, check for compressibility. Scan proximally to confirm the vein travels in a non-tortuous path and remains at approximately the same depth. The lumen should be large enough to be easily seen on the ultrasound screen, located anterior or adjacent, but never posterior, to an artery or nerve.

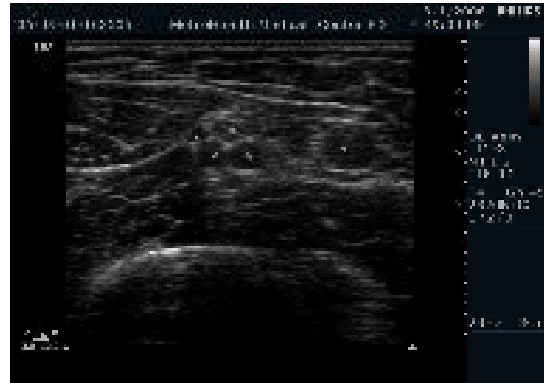


Figure 7 A and B. A. The antecubital fossa houses the deep brachial vein which is often posterior to the median nerve or the brachial artery. Do not go through the median nerve to get to the deep brachial vein. B. The basilic vein is more isolated and is frequently the safest choice in ultrasound-guided peripheral venous access.

Align the target vein in the center of the screen in short axis. Mark the entry point on the skin which aligns the center of the transducer over the center of the vein with either a needle cap or a marking pen. Some sonographers find that marking the skin in two points centered directly over the vein helps plan the direction of needle advancement (figure 8).

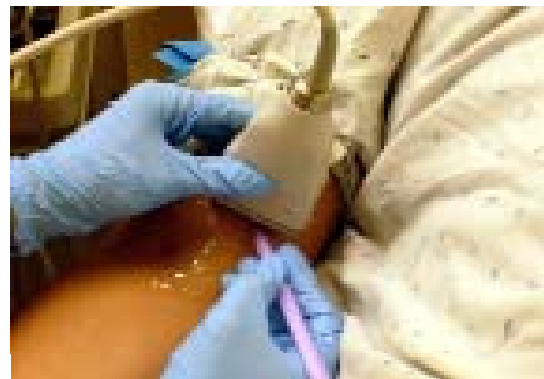


Figure 8. Marking the skin at the center of the transducer corresponds to the center of the screen where the targeted vein lies.

Puncture the skin and advance the needle either parallel (long axis) or perpendicular (short axis) to the long axis of the transducer face. Novice users prefer short axis to long axis [8]. Short axis illustrates whether or not the needle is aimed directly over the target. Long axis displays

correct angle of entry and confirmation of the needle tip within the vein lumen. Choice of technique is based on comfort level with short or long axis; many use both techniques in the same procedure. Never advance the needle blindly when you are targeting a deep vein. Only advance the needle if you are able to visualize the tip. The author starts in short axis to confirm the needle is headed directly for the target then changes to long axis to watch the needle tip enter the vein at an angle which facilitates advancing the angiocatheter for the longest length of catheter in the vein.

Secure the angiocatheter to the skin. Capture a picture of either the needle in the vein or if you do not have an extra hand when the needle is in the vein, acquire an image of the angiocatheter in the vein in long axis for documentation purposes (figure 9). Clean the machine including the transducer and transducer cord with a product specific for ultrasound equipment and return the machine to the proper location.

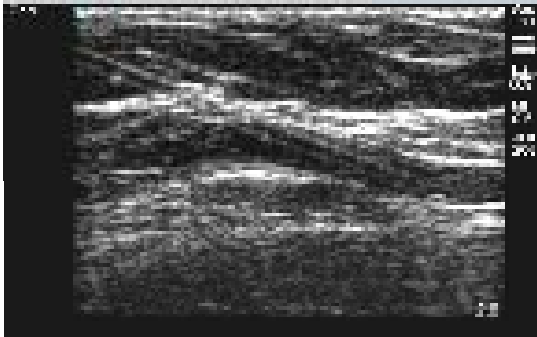


Figure 9. Long axis image of 1.88 inch angiocatheter in the basilic vein.

### Potential complications

The most common complications include arterial puncture, adjacent nerve irritation, and infiltration of the IV. Arterial puncture is documented to occur 2 percent of the time [4]. No long term nerve injury has been documented though nerve irritation has been documented in approximately one percent of cases [3,4]. Infiltration occurs in at least 8 percent of IVs [4]. Potential long-term complications, such as upper extremity deep venous thrombosis (UEDVT) and injury to veins which prevents arterio-venous fistula sites in renal patients, are not well documented in the current literature though concern of these issues has been published [9].

These IVs are not intended for long-term use as peripheral indwelling central catheters (PICCs) or as a substitute when a central line is indicated. PICCs are associated with up to 4.7 -11.4 percent incidence of UEDVT in subsets of oncology patients [10,11]. The risk of pulmonary embolism in patients with upper extremity deep venous thrombosis varies in the literature from insignificant to 36% but a higher percentage of PICC lines result in UEDVT and pulmonary emboli compared with central lines [10,12,13]. The risk of short-term use of upper extremity peripheral veins for emergency intravenous therapy and in-hospital use needs to be further studied.

### Common pitfalls

1. *My needle is under the skin but I can't see it on the ultrasound screen.*

Make sure the needle is directly underneath the face of the transducer. If you are using a linear transducer, the ultrasound waves travel only perpendicular to the long axis of the transducer face. Any echogenic surface that is not directly under the transducer face will not be seen on the ultrasound screen. Move the transducer closer to the site of skin entry. In short axis, you can try tilting the transducer face towards the skin entry site.

2. *I see my needle in long axis but now I don't see my vein.*

Take a deep breath. Move the transducer without tilting the transducer in the horizontal plane until you find your vein. Confirm that the target is indeed a vein but making sure it is not pulsating. You may have to switch to short axis at this point to verify compression because compression in long axis is not reliable. Augmentation is also helpful at this point to confirm you are heading towards a vein and not an artery. Think about which direction, right or left, you had to move the transducer to find the vein. Locate the needle again and advance the needle towards the vein.

3. *I buried my needle and I still can't reach the vein.*

The IV has a greater chance of infiltrating if the length of the catheter in the lumen is minimal, especially with deep veins. Retract the needle so

that you can advance at a steeper angle into the vein. If you still have a small length of needle and catheter in the vein, use the Seldinger technique to thread a longer angiocatheter in the vein.

**Conclusion**

Ultrasound-guided peripheral venous access is an increasingly popular, useful, and safe skill to use in emergency medicine. Planning the procedure with patience and awareness of arteries, nerves, and fascial planes is critical. Long-term complications of ultrasound-guided peripheral venous access need to be evaluated.

**References:**

1. Abboud PA, Kendall JL. Ultrasound guidance for vascular access. *Emerg Med Clin North Am*, 2004; 22(3):749-73.
2. Brannam L, et al. Emergency nurses' utilization of ultrasound guidance for placement of peripheral intravenous lines in difficult-access patients. *Acad Emerg Med*, 2004; 11(12):1361-3.
3. Costantino TG, et al. Ultrasonography-guided peripheral intravenous access versus traditional approaches in patients with difficult intravenous access. *Ann Emerg Med*, 2005; 46(5):456-61.
4. Keyes LE, et al. Ultrasound-guided brachial and basilic vein cannulation in emergency department patients with difficult intravenous access. *Ann Emerg Med*, 1999; 34(6):711-4.
5. Vyskocil JJ, Kruse JA, Wilson RF. Alternative techniques for gaining venous access. What to do when peripheral intravenous catheterization is not possible. *J Crit Illn*, 1993; 8(3):435-42.
6. Sandhu NP, Sidhu DS. Mid-arm approach to basilic and cephalic vein cannulation using ultrasound guidance. *Br J Anaesth*, 2004; 93(2):292-4.
7. Jones, R.L.a.n.b.D.J.
8. Blaivas M, Brannam L, Fernandez E. Short-axis versus long-axis approaches for teaching

ultrasound-guided vascular access on a new inanimate model. *Acad Emerg Med*, 2003; 10(12):1307-11.

9. Ault M, Letter to the editor: Ultrasound-guided brachial and basilic cannulation. *Annals of Emergency Medicine*, 2000; 36(4): p. 339.
10. Schimp VL, et al. Upper extremity deep vein thrombosis associated with indwelling peripheral venous catheters in gynecology oncology patients. *Gynecol Oncol*, 2003; 89(2):301-5.
11. Kuriakose P, Colon-Otero G, Paz-Fumagalli R. Risk of deep venous thrombosis associated with chest versus arm central venous subcutaneous port catheters: a 5-year single-institution retrospective study. *J Vasc Interv Radiol*, 2002; 13(2 Pt 1):179-84.
12. Prandoni P, Bernardi E, Upper extremity deep vein thrombosis. *Curr Opin Pulm Med*, 1999; 5(4):222-6.
13. Ellis MH, Manor Y, Witz M, Risk factors and management of patients with upper limb deep vein thrombosis. *Chest*, 2000; 117(1):43-6.

**Competing Interests:** None declared.

**Funding:** None

This manuscript has been peer reviewed

**Correspondence:**

Jessica Goldstein  
 2500 MetroHealth Drive  
 Department of Emergency Medicine  
 BG 6  
 Cleveland, OH 44109  
 Office: 216-778-3881  
 Fax: 216-778-2400

**e-mail:** [jgoldstein@metrohealth.org](mailto:jgoldstein@metrohealth.org)